A 23-year-old woman comes to the emergency department due to 2 hours of fever, chills, headache, and myalgias. Earlier in the day, the patient saw her primary care physician for a genital ulcer. She underwent testing for sexually transmitted infections and was found to have a positive VDRL. The remainder of her testing was negative. The patient received an intramuscular injection of benzathine penicillin G, and several hours later her current symptoms began. Temperature is 38 C (100.4 F), blood pressure is 120/70 mm Hg, and pulse is 92/min and regular. Lung sounds are normal. There is an indurated, nontender vulval ulcer and several enlarged inguinal lymph nodes. No other skin rash is present. Which of the following is the most likely cause of this patient's current symptoms?

A. Decreased activity of liver microsomal enzymes

B. Disease progression due to antibiotic resistance

C. Drug-induced bacterial disintegration

D. Immune sensitization from prior penicillin exposure

E. Poor renal tubular excretion of the drug

Submit

A 23-year-old woman comes to the emergency department due to 2 hours of fever, chills, headache, and myalgias. Earlier in the day, the patient saw her primary care physician for a genital ulcer. She underwent testing for sexually transmitted infections and was found to have a positive VDRL. The remainder of her testing was negative. The patient received an intramuscular injection of benzathine penicillin G, and several hours later her current symptoms began. Temperature is 38 C (100.4 F), blood pressure is 120/70 mm Hg, and pulse is 92/min and regular. Lung sounds are normal. There is an indurated, nontender vulval ulcer and several enlarged inguinal lymph nodes. No other skin rash is present. Which of the following is the most likely cause of this patient's current symptoms?

A. Decreased activity of liver microsomal enzymes (2%)

B. Disease progression due to antibiotic resistance (5%)

✓ C. Drug-induced bacterial disintegration (67%)

D. Immune sensitization from prior penicillin exposure (23%)

E. Poor renal tubular excretion of the drug (2%)

Omitted
Correct answer
C

67%
Answered correctly

03 secs
Time Spent

02/25/2020
Last Updated

Explanation

This patient with a genital ulcer, inguinal lymphadenopathy, and positive VDRL was treated for primary **syphilis** with intramuscular **benzathine penicillin G**. She then developed an acute febrile syndrome (fever, chills, myalgia, headache) a few hours later, raising strong suspicion for the **Jarisch-Herxheimer reaction**. This systemic inflammatory response occurs within hours of **antibiotic initiation** for spirochetal infections (eg, syphilis, Lyme disease, leptospirosis). The **rapid lysis of spirochetes** spills bacterial lipoproteins into the bloodstream and triggers a strong

C

Explanation

This patient with a genital ulcer, inguinal lymphadenopathy, and positive VDRL was treated for primary **syphilis** with intramuscular **benzathine penicillin G**. She then developed an acute febrile syndrome (fever, chills, myalgia, headache) a few hours later, raising strong suspicion for the **Jarisch-Herxheimer reaction**. This systemic inflammatory response occurs within hours of **antibiotic initiation** for spirochetal infections (eg, syphilis, Lyme disease, leptospirosis). The **rapid lysis of spirochetes** spills bacterial lipoproteins into the bloodstream and triggers a strong innate immunologic response. Most cases are self-limited and do not require intervention.

(Choices A and E) Intramuscular benzathine penicillin G is a long-acting drug that is excreted in the urine. The hepatic cytochrome system is not the primary mechanism of metabolism, so decreased microsomal liver enzyme activity would be unlikely to affect drug levels. Poor renal tubular secretion could increase plasma drug concentrations but would be unlikely to induce a systemic inflammatory response.

(Choice B) Syphilis is universally susceptible to penicillin. In addition, secondary syphilis (wide-spread maculopapular rash, constitutional symptoms, lymphadenopathy) develops weeks or months after the chancre of primary syphilis resolves, so disease progression is unlikely.

(Choice D) Penicillin allergy is due to immune sensitization following previous exposure. Additional exposure triggers an IgE-mediated (type I) allergic response; symptoms can range from mild (eg, urticaria) to severe (eg, laryngeal edema, circulatory collapse).

Educational objective:
The Jarisch-Herxheimer reaction is an acute inflammatory reaction that occurs within hours of treatment for spirochetal (eg, syphilis) infections. The rapid lysis of spirochetes releases inflammatory bacterial lipoproteins into the circulation and causes acute fevers, rigors, and myalgias.

Microbiology	Allergy & Immunology	Syphilis
Subject	System	Topic

Copyright © UWorld. All rights reserved.

A 19-year-old woman comes to the emergency department with pelvic pain, fever, and chills that began last night. The patient's last menstrual period was 12 weeks ago, and she had a surgical pregnancy termination at a clinic 2 days ago. Two weeks ago, she had fever, chills, a sore throat, and cough and was diagnosed with influenza, which resolved after a few days of rest. The patient's current temperature is 38.3 C (101 F), blood pressure is 92/60 mm Hg, and pulse is 102/min. Physical examination shows diffuse lower abdominal tenderness without any rebound or guarding. Speculum examination reveals an open cervical os, with foul-smelling tissue in the vaginal canal. Bimanual examination reveals moderate uterine tenderness and no adnexal masses. Which of the following is the most likely cause of this patient's condition?

A. *Chlamydia trachomatis*

B. *Gardnerella vaginalis*

C. Influenza A virus

D. *Listeria monocytogenes*

E. *Staphylococcus aureus*

Submit

A 19-year-old woman comes to the emergency department with pelvic pain, fever, and chills that began last night. The patient's last menstrual period was 12 weeks ago, and she had a surgical pregnancy termination at a clinic 2 days ago. Two weeks ago, she had fever, chills, a sore throat, and cough and was diagnosed with influenza, which resolved after a few days of rest. The patient's current temperature is 38.3 C (101 F), blood pressure is 92/60 mm Hg, and pulse is 102/min. Physical examination shows diffuse lower abdominal tenderness without any rebound or guarding. Speculum examination reveals an open cervical os, with foul-smelling tissue in the vaginal canal. Bimanual examination reveals moderate uterine tenderness and no adnexal masses. Which of the following is the most likely cause of this patient's condition?

A. *Chlamydia trachomatis* (18%)

B. *Gardnerella vaginalis* (27%)

C. Influenza A virus (0%)

D. *Listeria monocytogenes* (3%)

✓ E. *Staphylococcus aureus* (49%)

Omitted
Correct answer
E

49%
Answered correctly

02 secs
Time Spent

05/03/2020
Last Updated

Explanation

Septic abortion

Septic abortion	
Risk factors	Pregnancy termination with retained products of conception
Microbiology	• Gram-negative bacilli • *Staphylococcus aureus*
Clinical presentation	• Fever, chills, lower abdominal pain, bloody or purulent vaginal discharge • Boggy & tender uterus with dilated cervix • Pelvic ultrasound: Retained products of conception, increased vascularity, echogenic material in the cavity, thick endometrial stripe

©UWorld

Septic abortion refers to any type of abortion resulting in infected **retained products of conception** in the uterine cavity. In industrialized countries, it is a rare complication of pregnancy termination and may occur with incomplete evacuation of products of conception. Patients with septic abortion typically have fever, abdominal pain, uterine tenderness, and/or a foul-smelling vaginal discharge.

Staphylococcus aureus is a very common pathogen in septic abortion; other causative organisms include gram-negative bacilli (eg, *Escherichia coli*) and group B *Streptococcus*. These organisms are part of normal vaginal flora and seed the uterine cavity during instrumentation, thereafter proliferating in the retained tissue. Most infections associated with septic abortion are confined to the placental tissue, but patients can become septic if toxin-producing bacteria gain access to the intervillous space and bloodstream.

Treatment includes broad-spectrum **antibiotics** and prompt **surgical evacuation** to remove the nidus of infection and prevent severe complications such as sepsis, multi-organ failure, and death. Long-term complications include synechiae (adhesions) in the uterine cavity that can

©UWorld

Septic abortion refers to any type of abortion resulting in infected **retained products of conception** in the uterine cavity. In industrialized countries, it is a rare complication of pregnancy termination and may occur with incomplete evacuation of products of conception. Patients with septic abortion typically have fever, abdominal pain, uterine tenderness, and/or a foul-smelling vaginal discharge.

Staphylococcus aureus is a very common pathogen in septic abortion; other causative organisms include gram-negative bacilli (eg, *Escherichia coli*) and group B *Streptococcus*. These organisms are part of normal vaginal flora and seed the uterine cavity during instrumentation, thereafter proliferating in the retained tissue. Most infections associated with septic abortion are confined to the placental tissue, but patients can become septic if toxin-producing bacteria gain access to the intervillous space and bloodstream.

Treatment includes broad-spectrum **antibiotics** and prompt **surgical evacuation** to remove the nidus of infection and prevent severe complications such as sepsis, multi-organ failure, and death. Long-term complications include synechiae (adhesions) in the uterine cavity that can lead to secondary amenorrhea and infertility (**Asherman syndrome**).

(Choice A) *Chlamydia trachomatis* can cause cervicitis and pelvic inflammatory disease characterized by pelvic pain with fever and cervical motion tenderness. This pathogen is not typically involved in septic abortion.

(Choice B) *Gardnerella vaginalis* is part of the normal vaginal bacterial flora. An imbalance in the vaginal ecosystem can cause overgrowth of this bacterium, resulting in the characteristic foul-smelling discharge of bacterial vaginosis (BV). Patients with BV do not present with fever or uterine tenderness.

(Choice C) Influenza can cause severe systemic illness with respiratory compromise in pregnant women, but it does not lead to localized intrauterine infection such as septic abortion.

(Choice D) *Listeria monocytogenes* is a foodborne pathogen that is especially virulent in immunocompromised individuals and pregnant women. It is not introduced through uterine instrumentation during pregnancy termination. Infection with this organism can cause miscarriage, chorioamnionitis, and/or neonatal sepsis.

Educational objective:
Septic abortion typically presents with fever, abdominal pain, uterine tenderness, and/or foul-smelling discharge after pregnancy termination. Common offending pathogens include *Staphylococcus aureus* and *Escherichia coli* due to seeding of the uterine cavity during instrumentation.

Treatment includes broad-spectrum **antibiotics** and prompt **surgical evacuation** to remove the nidus of infection and prevent severe complications such as sepsis, multi-organ failure, and death. Long-term complications include synechiae (adhesions) in the uterine cavity that can lead to secondary amenorrhea and infertility (**Asherman syndrome**).

(Choice A) *Chlamydia trachomatis* can cause cervicitis and pelvic inflammatory disease characterized by pelvic pain with fever and cervical motion tenderness. This pathogen is not typically involved in septic abortion.

(Choice B) *Gardnerella vaginalis* is part of the normal vaginal bacterial flora. An imbalance in the vaginal ecosystem can cause overgrowth of this bacterium, resulting in the characteristic foul-smelling discharge of bacterial vaginosis (BV). Patients with BV do not present with fever or uterine tenderness.

(Choice C) Influenza can cause severe systemic illness with respiratory compromise in pregnant women, but it does not lead to localized intrauterine infection such as septic abortion.

(Choice D) *Listeria monocytogenes* is a foodborne pathogen that is especially virulent in immunocompromised individuals and pregnant women. It is not introduced through uterine instrumentation during pregnancy termination. Infection with this organism can cause miscarriage, chorioamnionitis, and/or neonatal sepsis.

Educational objective:
Septic abortion typically presents with fever, abdominal pain, uterine tenderness, and/or foul-smelling discharge after pregnancy termination. Common offending pathogens include *Staphylococcus aureus* and *Escherichia coli* due to seeding of the uterine cavity during instrumentation.

References

- Treating spontaneous and induced septic abortions.

Microbiology	Female Reproductive System & Breast	Abortion
Subject	System	Topic

Copyright © UWorld. All rights reserved.

Exhibit Display

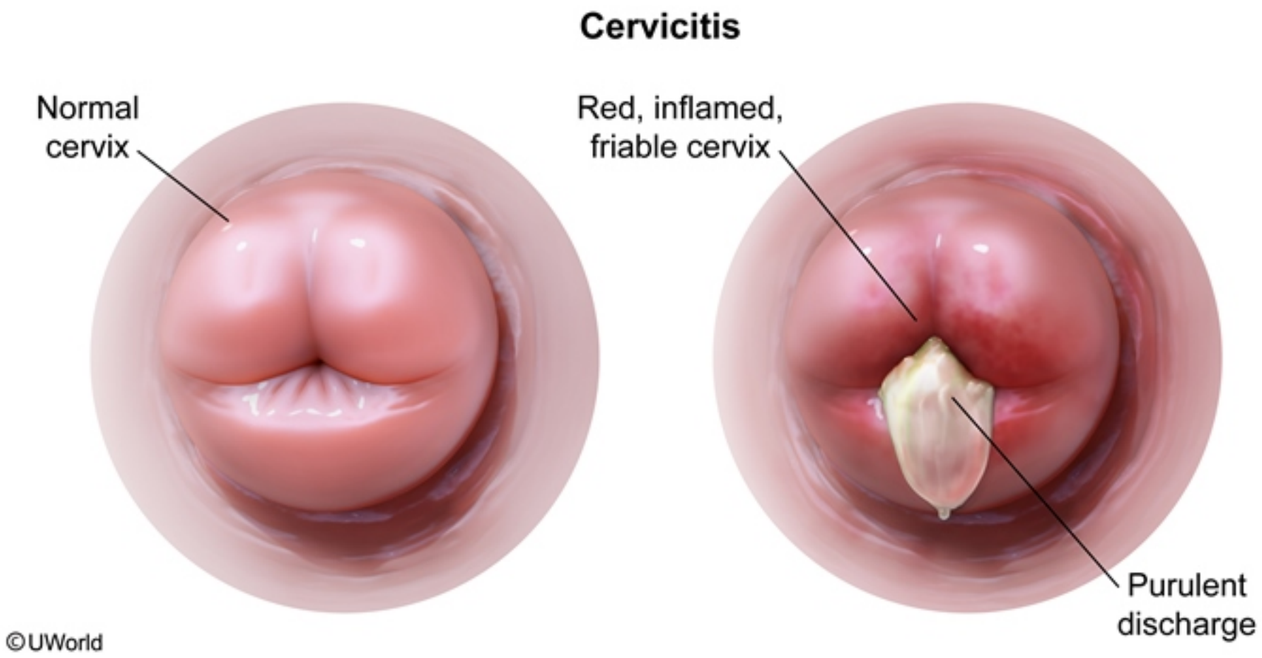

Zoom In | Zoom Out | Reset | Add To New Card | Existing Card

A 36-year-old man comes to the office to discuss a skin rash on his shoulders and upper chest. The patient first noticed the rash 2 months ago while vacationing at a beach resort. The rash has worsened progressively and is associated with mild pruritus, but he has no other associated symptoms. The patient is a road construction worker, and often works in hot, humid areas. Past medical history is notable for seasonal allergies and childhood asthma. He does not use tobacco or alcohol. Skin examination findings are shown in the image below.

Settings

1
2
3
4
5
6
7
8
9
10
11
12
13
14
15
16
17
18
19
20
21
22
23
24
25
26
27
28
29
30

Item 3 of 33
Question Id: 104

Mark

Previous Next Full Screen Tutorial Lab Values Notes Calculator Reverse Color Text Zoom Settings

Which of the following is the most likely cause of this patient's condition?

A. *Blastomyces dermatitidis*

Block Time Remaining: 00:00:07
TUTOR

8 Feedback Suspend End Block

Which of the following is the most likely cause of this patient's condition?

- A. *Blastomyces dermatitidis*
- B. *Candida albicans*
- C. *Histoplasma capsulatum*
- D. *Malassezia globosa*
- E. *Microsporum canis*
- F. *Rhizopus species*
- G. *Sporothrix schenckii*

Submit

Which of the following is the most likely cause of this patient's condition?

- A. *Blastomyces dermatitidis* (8%)
- B. *Candida albicans* (3%)
- C. *Histoplasma capsulatum* (1%)
- ✓ D. *Malassezia globosa* (75%)
- E. *Microsporum canis* (6%)
- F. *Rhizopus species* (2%)
- G. *Sporothrix schenckii* (2%)

Omitted
Correct answer

75%
Answered correctly

06 secs
Time Spent

06/20/2020
Last Updated

Medically important fungi	
Cutaneous	• Dermatophytosis (eg, tinea, onychomycosis) • Pityriasis versicolor
Subcutaneous	• Sporotrichosis
Systemic	• Histoplasmosis • Coccidioidomycosis • Blastomycosis
Opportunistic	• *Candida* • *Aspergillus* • *Mucor* • *Rhizopus*

©UWorld

Pityriasis versicolor (also called tinea versicolor) is characterized by hypopigmented, hyperpigmented, or erythematous macules or patches on the upper body. It is caused by *Malassezia* species yeasts, and the infection is confined to the **stratum corneum** of the skin. It is common in areas with hot and humid climates and is often most **visible after** extensive sun exposure due to **tanning of the adjacent skin**. Most cases of pityriasis versicolor occur in healthy individuals with no underlying immunologic deficiencies.

The diagnosis of pityriasis versicolor is made by potassium hydroxide **(KOH) preparation** of skin scrapings. *Malassezia* forms spores and hyphae, producing the characteristic "**spaghetti and meatballs**" appearance on light microscopy. The hyphae have a short, "cigar-butt" appearance. This condition is treated with topical antifungal agents or selenium-containing shampoo.

Pityriasis versicolor (also called tinea versicolor) is characterized by hypopigmented, hyperpigmented, or erythematous macules or patches on the upper body. It is caused by *Malassezia* species yeasts, and the infection is confined to the **stratum corneum** of the skin. It is common in areas with hot and humid climates and is often most **visible after** extensive sun exposure due to **tanning of the adjacent skin**. Most cases of pityriasis versicolor occur in healthy individuals with no underlying immunologic deficiencies.

The diagnosis of pityriasis versicolor is made by potassium hydroxide **(KOH) preparation** of skin scrapings. *Malassezia* forms spores and hyphae, producing the characteristic "**spaghetti and meatballs**" appearance on light microscopy. The hyphae have a short, "cigar-butt" appearance. This condition is treated with topical antifungal agents or selenium-containing shampoo.

(Choices A and C) Blastomycosis is characterized by progressive pulmonary infection. Skin involvement is uncommon but can manifest as papular or pustular lesions in exposed areas. Histoplasmosis also most commonly causes pulmonary disease, though it may become disseminated in immunodeficient patients.

(Choice B) Intertrigo is characterized by well-defined erythematous plaques with satellite vesicles or pustules in warm, moist skin areas (eg, axillae, groin, skin folds). The infection is usually due to *Candida* species, and it is most common following antibiotic use or in immunocompromised states (eg, uncontrolled diabetes).

(Choice E) *Microsporum* species are a frequent cause of tinea capitis and tinea corporis.

(Choice F) *Rhizopus* is a major cause of mucormycosis, which is characterized by invasive, necrotic upper and lower respiratory infections in immunocompromised patients.

(Choice G) *Sporothrix* molds are found in decaying horticultural matter and are acquired through breaks in the skin. They cause nodular and ulcerating subcutaneous lesions.

Educational objective:
Pityriasis versicolor (tinea versicolor) is a superficial skin infection caused by *Malassezia* species. It causes erythematous, hyper- or hypopigmented macules and patches. *Malassezia* forms spores and hyphae, producing the characteristic "spaghetti and meatballs" appearance on KOH preparation light microscopy.

References

- Microreview of pityriasis versicolor and Malassezia species

hyphae, producing the characteristic "**spaghetti and meatballs**" appearance on light microscopy. The hyphae have a short, "cigar-butt" appearance. This condition is treated with topical antifungal agents or selenium-containing shampoo.

(Choices A and C) Blastomycosis is characterized by progressive pulmonary infection. Skin involvement is uncommon but can manifest as papular or pustular lesions in exposed areas. Histoplasmosis also most commonly causes pulmonary disease, though it may become disseminated in immunodeficient patients.

(Choice B) Intertrigo is characterized by well-defined erythematous plaques with satellite vesicles or pustules in warm, moist skin areas (eg, axillae, groin, skin folds). The infection is usually due to *Candida* species, and it is most common following antibiotic use or in immunocompromised states (eg, uncontrolled diabetes).

(Choice E) *Microsporum* species are a frequent cause of tinea capitis and tinea corporis.

(Choice F) *Rhizopus* is a major cause of mucormycosis, which is characterized by invasive, necrotic upper and lower respiratory infections in immunocompromised patients.

(Choice G) *Sporothrix* molds are found in decaying horticultural matter and are acquired through breaks in the skin. They cause nodular and ulcerating subcutaneous lesions.

Educational objective:
Pityriasis versicolor (tinea versicolor) is a superficial skin infection caused by *Malassezia* species. It causes erythematous, hyper- or hypopigmented macules and patches. *Malassezia* forms spores and hyphae, producing the characteristic "spaghetti and meatballs" appearance on KOH preparation light microscopy.

References

- Microreview of pityriasis versicolor and Malassezia species.

Microbiology	Dermatology	Tinea
Subject	System	Topic

Copyright © UWorld. All rights reserved.

Settings

1 2 3 4 5 6 7 8 9 10 11 12 13 14 15 16 17 18 19 20 21 22 23 24 25 26 27 28 29 30

Item 3 of 33
Question Id: 104

Mark | Previous | Next | Full Screen | Tutorial | Lab Values | Notes | Calculator | Reverse Color | Text Zoom | Settings

hyphae, producing the characteristic "**spaghetti and meatballs**" appearance on light microscopy. The hyphae have a short, "cigar-butt"

Exhibit Display

Zoom In | Zoom Out | Reset | Add To New Card | Existing Card

Copyright © UWorld. All rights reserved.

Block Time Remaining: 00:00:11
TUTOR

8 | Feedback | Suspend | End Block

Settings

1
2
3
4
5
6
7
8
9
10
11
12
13
14
15
16
17
18
19
20
21
22
23
24
25
26
27
28
29
30

Item 3 of 33
Question Id: 104

Mark | Previous | Next | Full Screen | Tutorial | Lab Values | Notes | Calculator | Reverse Color | Text Zoom | Settings

hyphae, producing the characteristic "**spaghetti and meatballs**" appearance on light microscopy. The hyphae have a short, "cigar-butt"

Exhibit Display

Zoom In | Zoom Out | Reset | Add To New Card | Existing Card

Copyright © UWorld. All rights reserved.

Block Time Remaining: 00:00:11
TUTOR

8 | Feedback | Suspend | End Block

Settings

1
2
3
4
5
6
7
8
9
10
11
12
13
14
15
16
17
18
19
20
21
22
23
24
25
26
27
28
29
30

Item 3 of 33
Question Id: 104

Mark | Previous | Next | Full Screen | Tutorial | Lab Values | Notes | Calculator | Reverse Color | Text Zoom | Settings

hyphae, producing the characteristic "**spaghetti and meatballs**" appearance on light microscopy. The hyphae have a short, "cigar-butt"

Exhibit Display

Zoom In | Zoom Out | Reset | Add To New Card | Existing Card

Copyright © USMLE World. All rights reserved.

Block Time Remaining: 00:00:11
TUTOR

8 | Feedback | Suspend | End Block

Settings

1
2
3
4
5
6
7
8
9
10
11
12
13
14
15
16
17
18
19
20
21
22
23
24
25
26
27
28
29
30

Item 3 of 33
Question Id: 104

Mark | Previous | Next | Full Screen | Tutorial | Lab Values | Notes | Calculator | Reverse Color | Text Zoom | Settings

hyphae, producing the characteristic "**spaghetti and meatballs**" appearance on light microscopy. The hyphae have a short, "cigar-butt"

Exhibit Display

Zoom In | Zoom Out | Reset | Add To New Card | Existing Card

Copyright © UWorld. All rights reserved.

Block Time Remaining: 00:00:11
TUTOR

8 | Feedback | Suspend | End Block

Settings

1 2 3 4 5 6 7 8 9 10 11 12 13 14 15 16 17 18 19 20 21 22 23 24 25 26 27 28 29 30

Item 3 of 33
Question Id: 104

Mark | Previous | Next | Full Screen | Tutorial | Lab Values | Notes | Calculator | Reverse Color | Text Zoom | Settings

hyphae, producing the characteristic "**spaghetti and meatballs**" appearance on light microscopy. The hyphae have a short, "cigar-butt"

Exhibit Display

Zoom In | Zoom Out | Reset | Add To New Card | Existing Card

Copyright © USMLE World. All rights reserved.

Block Time Remaining: 00:00:11
TUTOR

8 | Feedback | Suspend | End Block

Settings

1
2
3
4
5
6
7
8
9
10
11
12
13
14
15
16
17
18
19
20
21
22
23
24
25
26
27
28
29
30

Item 3 of 33
Question Id: 104

Mark | Previous | Next | Full Screen | Tutorial | Lab Values | Notes | Calculator | Reverse Color | Text Zoom | Settings

hyphae, producing the characteristic "**spaghetti and meatballs**" appearance on light microscopy. The hyphae have a short, "cigar-butt"

Exhibit Display

Zoom In | Zoom Out | Reset | Add To New Card | Existing Card

Copyright © UWorld. All rights reserved.

Block Time Remaining: 00:00:11
TUTOR

8 | Feedback | Suspend | End Block

A 66-year-old man comes to the emergency department due to a 3-day history of fever, chills, dysuria, and perineal pain. The patient has never had similar symptoms before, although he has had occasional nocturia and urinary hesitancy over the last 2 years. His other medical conditions include type 2 diabetes mellitus and hypertension. The patient does not use tobacco, alcohol, or illicit drugs. He has not traveled recently and is not sexually active. Temperature is 39 C (102.2 F), blood pressure is 124/78 mm Hg, and pulse is 106/min. The abdomen is soft and nontender with no costovertebral angle tenderness. Digital rectal examination shows a smoothly enlarged and tender prostate. External genitalia are normal with no scrotal tenderness. There is no urethral discharge. The remainder of the examination shows no abnormalities. Urinalysis reveals bacteriuria and pyuria. Which of the following pathogens is most likely responsible for this patient's current symptoms?

- A. *Chlamydia trachomatis*
- B. *Coccidioides immitis*
- C. *Escherichia coli*
- D. *Mycoplasma hominis*
- E. *Neisseria gonorrhoeae*
- F. *Staphylococcus aureus*
- G. *Staphylococcus saprophyticus*
- H. *Ureaplasma urealyticum*

Submit

A 66-year-old man comes to the emergency department due to a 3-day history of fever, chills, dysuria, and perineal pain. The patient has never had similar symptoms before, although he has had occasional nocturia and urinary hesitancy over the last 2 years. His other medical conditions include type 2 diabetes mellitus and hypertension. The patient does not use tobacco, alcohol, or illicit drugs. He has not traveled recently and is not sexually active. Temperature is 39 C (102.2 F), blood pressure is 124/78 mm Hg, and pulse is 106/min. The abdomen is soft and nontender with no costovertebral angle tenderness. Digital rectal examination shows a smoothly enlarged and tender prostate. External genitalia are normal with no scrotal tenderness. There is no urethral discharge. The remainder of the examination shows no abnormalities. Urinalysis reveals bacteriuria and pyuria. Which of the following pathogens is most likely responsible for this patient's current symptoms?

- A. *Chlamydia trachomatis* (1%)
- B. *Coccidioides immitis* (0%)
- ✓ C. *Escherichia coli* (91%)
- D. *Mycoplasma hominis* (0%)
- E. *Neisseria gonorrhoeae* (0%)
- F. *Staphylococcus aureus* (2%)
- G. *Staphylococcus saprophyticus* (0%)
- H. *Ureaplasma urealyticum* (2%)

Omitted
Correct answer
C

91%
Answered correctly

02 secs
Time Spent

03/21/2020
Last Updated

Acute bacterial prostatitis	
Etiology	• Reflux of urine & organisms from bladder & urethra • Mostly **gram-negative bacilli** (majority *Escherichia coli*)
Clinical presentation	• Systemic symptoms (eg, fever, chills) • Lower urinary tract symptoms (eg, dysuria, urine retention, pelvic pain) • Examination: swollen, tender prostate
Diagnosis	• Urine Gram stain & culture

This patient has fever, dysuria, and prostatic tenderness, consistent with **acute bacterial prostatitis** (ABP). ABP is most commonly caused by reflux of urine and organisms from the bladder and urethra into the prostatic ducts, although it can occasionally be caused by direct inoculation (eg, prostate biopsy) or hematogenous seeding from remote infection (eg, endocarditis). The risk of developing ABP is greater in patients with diabetes mellitus, anatomic abnormalities (eg, strictures), or bladder catheterization.

As with other urinary tract infections, the most common organisms in ABP include **enteric gram-negative bacilli**, predominantly ***Escherichia coli***, because of virulence factors (eg, adhesins on bacterial fimbriae) that allow it to adhere onto mucosal or urothelial cells. The other bacteria (also gram-negative bacilli) that commonly cause ABP include *Proteus*, *Klebsiella*, *Pseudomonas*.

(Choices A and E) Sexually transmitted organisms (eg, *Chlamydia trachomatis*, *Neisseria gonorrhoeae*) commonly cause urethritis and/or urogenital infections that can involve the prostate, but this typically occurs in younger, sexually active men (this patient is older and not sexually active).

(Choice B) *Coccidioides* infections most commonly cause community-acquired pneumonia in endemic areas (eg, California, Arizona), but they can also cause dermatologic (eg, erythema nodosum or multiforme) or rheumatologic (eg, arthralgias) manifestations.

(Choices D and H) *Mycoplasma hominis* and *Ureaplasma urealyticum* commonly colonize the genitourinary tract, but they have not been proven

This patient has fever, dysuria, and prostatic tenderness, consistent with **acute bacterial prostatitis** (ABP). ABP is most commonly caused by reflux of urine and organisms from the bladder and urethra into the prostatic ducts, although it can occasionally be caused by direct inoculation (eg, prostate biopsy) or hematogenous seeding from remote infection (eg, endocarditis). The risk of developing ABP is greater in patients with diabetes mellitus, anatomic abnormalities (eg, strictures), or bladder catheterization.

As with other urinary tract infections, the most common organisms in ABP include **enteric gram-negative bacilli**, predominantly ***Escherichia coli***, because of virulence factors (eg, adhesins on bacterial fimbriae) that allow it to adhere onto mucosal or urothelial cells. The other bacteria (also gram-negative bacilli) that commonly cause ABP include *Proteus*, *Klebsiella*, *Pseudomonas*.

(Choices A and E) Sexually transmitted organisms (eg, *Chlamydia trachomatis*, *Neisseria gonorrhoeae*) commonly cause urethritis and/or urogenital infections that can involve the prostate, but this typically occurs in younger, sexually active men (this patient is older and not sexually active).

(Choice B) *Coccidioides* infections most commonly cause community-acquired pneumonia in endemic areas (eg, California, Arizona), but they can also cause dermatologic (eg, erythema nodosum or multiforme) or rheumatologic (eg, arthralgias) manifestations.

(Choices D and H) *Mycoplasma hominis* and *Ureaplasma urealyticum* commonly colonize the genitourinary tract, but they have not been proven to be a significant cause of symptomatic genitourinary infections.

(Choice F) Gram-positive skin flora (eg, *Staphylococcus aureus*) most commonly cause skin and soft tissue infections. Although patients with *S aureus* bacteremia can develop localized infections throughout the body (eg, endocarditis, osteomyelitis, organ abscess), isolated ABP would be rare.

(Choice G) Coagulase-negative staphylococci (eg, *S saprophyticus*) are a common cause of acute cystitis in young women.

Educational objective:
Acute bacterial prostatitis is usually caused by reflux of urine and organisms from the bladder and urethra. The risk is greater in patients with anatomic abnormalities (eg, strictures) or bladder catheterization. *Escherichia coli* is the most common cause of acute bacterial prostatitis and other urinary tract infections because of adhesins on its fimbriae that promote adherence to urothelial or mucosal cells.

References

- Acute bacterial prostatitis: diagnosis and management.

(Choices A and E) Sexually transmitted organisms (eg, *Chlamydia trachomatis*, *Neisseria gonorrhoeae*) commonly cause urethritis and/or urogenital infections that can involve the prostate, but this typically occurs in younger, sexually active men (this patient is older and not sexually active).

(Choice B) *Coccidioides* infections most commonly cause community-acquired pneumonia in endemic areas (eg, California, Arizona), but they can also cause dermatologic (eg, erythema nodosum or multiforme) or rheumatologic (eg, arthralgias) manifestations.

(Choices D and H) *Mycoplasma hominis* and *Ureaplasma urealyticum* commonly colonize the genitourinary tract, but they have not been proven to be a significant cause of symptomatic genitourinary infections.

(Choice F) Gram-positive skin flora (eg, *Staphylococcus aureus*) most commonly cause skin and soft tissue infections. Although patients with *S aureus* bacteremia can develop localized infections throughout the body (eg, endocarditis, osteomyelitis, organ abscess), isolated ABP would be rare.

(Choice G) Coagulase-negative staphylococci (eg, *S saprophyticus*) are a common cause of acute cystitis in young women.

Educational objective:
Acute bacterial prostatitis is usually caused by reflux of urine and organisms from the bladder and urethra. The risk is greater in patients with anatomic abnormalities (eg, strictures) or bladder catheterization. *Escherichia coli* is the most common cause of acute bacterial prostatitis and other urinary tract infections because of adhesins on its fimbriae that promote adherence to urothelial or mucosal cells.

References

- Acute bacterial prostatitis: diagnosis and management.
- The etiology and management of acute prostatitis.

Microbiology	Male Reproductive System	Prostatitis
Subject	System	Topic

Copyright © UWorld. All rights reserved.

A 15-year-old, previously healthy girl comes to the office for evaluation of vaginal discharge that began 5 days ago. The discharge is grayish-white in color and fishy-smelling; her vagina is mildly itchy. She is sexually active with one male partner who is inconsistent with condom use. Her temperature is 36.7 C (98 F), blood pressure is 106/52 mm Hg, and pulse is 78/min. Examination shows a small amount of grayish discharge in the vaginal vault. Her cervix appears normal. Which of the following would most likely be seen on microscopy?

A. Epithelial cells covered with gram-variable rods

B. Epithelial cells with rare leukocytes

C. Gram-negative intracellular diplococci

D. Leukocytes and pear-shaped organisms

E. Pseudohyphae with leukocytes

Submit

A 15-year-old, previously healthy girl comes to the office for evaluation of vaginal discharge that began 5 days ago. The discharge is grayish-white in color and fishy-smelling; her vagina is mildly itchy. She is sexually active with one male partner who is inconsistent with condom use. Her temperature is 36.7 C (98 F), blood pressure is 106/52 mm Hg, and pulse is 78/min. Examination shows a small amount of grayish discharge in the vaginal vault. Her cervix appears normal. Which of the following would most likely be seen on microscopy?

- ✓ A. Epithelial cells covered with gram-variable rods (75%)
- B. Epithelial cells with rare leukocytes (5%)
- C. Gram-negative intracellular diplococci (4%)
- D. Leukocytes and pear-shaped organisms (11%)
- E. Pseudohyphae with leukocytes (3%)

Omitted
Correct answer
A

75%
Answered correctly

02 secs
Time Spent

06/15/2020
Last Updated

Explanation

Differential diagnosis of vaginitis

Diagnosis	Bacterial vaginosis (*Gardnerella vaginalis*)	Trichomoniasis (*Trichomonas vaginalis*)	Candida vaginitis (*Candida albicans*)

Differential diagnosis of vaginitis

Diagnosis	Bacterial vaginosis (*Gardnerella vaginalis*)	Trichomoniasis (*Trichomonas vaginalis*)	Candida vaginitis (*Candida albicans*)
Examination	• Thin, off-white discharge with fishy odor • No inflammation	• Thin, yellow-green, malodorous, frothy discharge • Vaginal inflammation	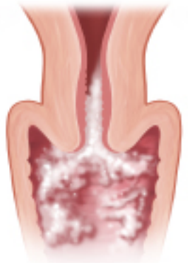 • Thick, "cottage cheese" discharge • Vaginal inflammation
Laboratory findings	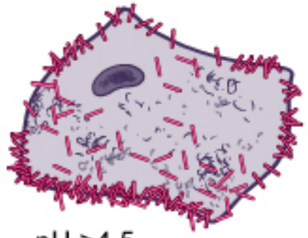 • pH >4.5 • Clue cells • Positive whiff test (amine odor with KOH)	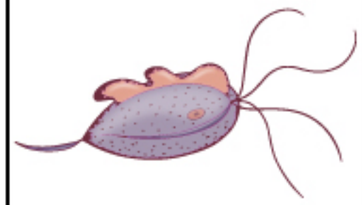 • pH >4.5 • Motile trichomonads	• Normal pH (3.8-4.5) • Pseudohyphae
Treatment	Metronidazole or clindamycin	Metronidazole; treat sexual partner	Fluconazole

KOH = potassium hydroxide.

©UWorld

This patient's clinical presentation is most consistent with **bacterial vaginosis**. Bacterial vaginosis is caused by an imbalance of the vaginal bacterial flora, which results in an overgrowth of *Gardnerella vaginalis*. It presents with a **grayish-white, "fishy-smelling,"** and mildly **pruritic vaginal discharge**. **Clue cells** (epithelial cells covered with gram-variable rods) are seen on wet mount microscopy. Sexual intercourse increases the risk for bacterial vaginosis, especially when an individual has multiple partners.

The treatment of choice is **metronidazole** or **clindamycin**. Treatment of male partners is not recommended as men are asymptomatic; treatment of male partners would not affect the patient's recovery course. Treatment of female partners is only indicated if the woman is symptomatic.

(Choice B) A wet mount with epithelial cells and rare leukocytes is consistent with normal vaginal discharge (leukorrhea).

(Choice C) Gonorrhea cervicitis is characterized by cervical erythema/friability, purulent vaginal discharge, and a Gram stain that shows gram-negative intracellular diplococci.

(Choice D) A wet mount with leukocytes and pear-shaped organisms describes trichomonas vaginitis.

(Choice E) Pseudohyphae with leukocytes are seen in Candida vaginitis.

Educational objective:
Bacterial vaginosis is caused by a disruption of the vaginal bacteria flora and is characterized by a "fishy-smelling," thin, grayish vaginal discharge and clue cells on wet mount microscopy. Metronidazole and clindamycin are the preferred treatment options.

References

- Diagnosis of vaginal discharge by wet mount microscopy: a simple and underrated method.
- Vaginitis.
- Sexually transmitted diseases.
- Trichomonas vaginalis in selected U.S. sexually transmitted disease clinics: testing, screening, and prevalence.

Settings

1 2 3 4 5 6 7 8 9 10 11 12 13 14 15 16 17 18 19 20 21 22 23 24 25 26 27 28 29 30

Item 5 of 33
Question Id: 11765

Mark | Previous | Next | Full Screen | Tutorial | Lab Values | Notes | Calculator | Reverse Color | Text Zoom | Settings

Exhibit Display

Zoom In | Zoom Out | Reset | Add To New Card | Existing Card

Block Time Remaining: 00:00:15
TUTOR

3 | Feedback | Suspend | End Block

A 60-year-old woman comes to the physician with 10 days of diffuse itching. A rash began on her hands and quickly spread to involve her wrists, arms, and axillae. She has difficulty sleeping and complains of intense itching in these areas. She works in a day care center and primarily takes care of children age 2-5. The patient has no other medical conditions and takes no chronic medications. Vital signs are normal. Her BMI is 24 kg/m^2. Skin examination shows small erythematous papules on the palms with excoriations, scattered vesicles, and pustules on the finger webs, palms, and wrist creases, as seen in the image below. She has similar lesions in her axillary skin folds bilaterally. The remainder of the examination is within normal limits.

Which of the following is the most likely finding on skin sampling of this patient's lesions?

A. Budding yeast

B. Molluscum bodies

C. Multinucleated giant cells

D. Necrotic keratinocytes in the epidermis

E. *Sarcoptes scabiei* mite and eggs

Submit

1 2 3 4 5 6 7 8 9 10 11 12 13 14 15 16 17 18 19 20 21 22 23 24 25 26 27 28 29 30

Which of the following is the most likely finding on skin sampling of this patient's lesions?

A. Budding yeast (2%)

B. Molluscum bodies (11%)

C. Multinucleated giant cells (11%)

D. Necrotic keratinocytes in the epidermis (6%)

✓ E. *Sarcoptes scabiei* mite and eggs (67%)

Omitted
Correct answer

67%
Answered correctly

05 secs
Time Spent

04/26/2020
Last Updated

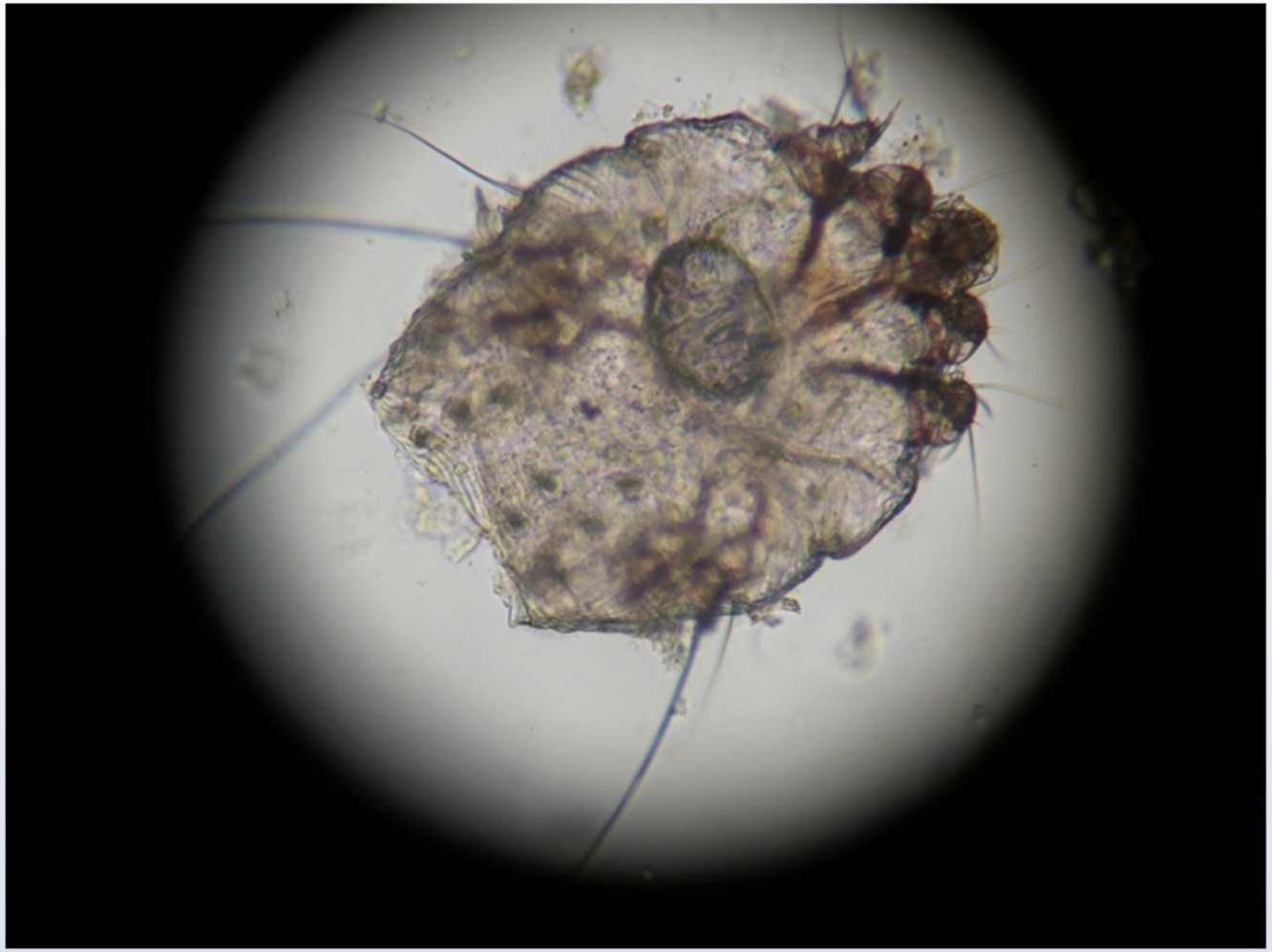

This patient's presentation – rapidly spreading, pruritic rash with erythematous papules and excoriations on the extremities - suggests scabies. Scabies is due to infestation by the *Sarcoptes scabiei* mite, which burrows into the skin and spreads through direct person-to-person contact. It usually presents with an intensely pruritic rash in the flexor surfaces of the wrist, lateral surfaces of the fingers, and the finger webs. The rash is often worse at night and is due to a delayed type IV hypersensitivity reaction to the mite, mite feces, and mite eggs. Scabies can also involve

This patient's presentation – rapidly spreading, pruritic rash with erythematous papules and excoriations on the extremities - suggests scabies. Scabies is due to infestation by the *Sarcoptes scabiei* mite, which burrows into the skin and spreads through direct person-to-person contact. It usually presents with an intensely pruritic rash in the flexor surfaces of the wrist, lateral surfaces of the fingers, and the finger webs. The rash is often worse at night and is due to a delayed type IV hypersensitivity reaction to the mite, mite feces, and mite eggs. Scabies can also involve other parts of the body (eg, elbows, axillary folds, nipples, and areola in women; scrotum and penis in men), but less commonly affects the back and head (except in children).

Skin examination usually shows excoriations with small, crusted, red papules scattered around the region. Patients can also develop small vesicles, pustules, or wheals. Linear burrows are the most specific finding in scabies, although they are often obscured by excoriations. Diagnosis is confirmed by skin scrapings from excoriated lesions that show mites, ova, and feces under light microscopy, as shown in the image above.

(Choice A) Budding yeast indicates *Candida* infection, which most commonly occurs in skin folds with increased moisture and friction. Risk factors include obesity or conditions that interfere with the immune system (eg, diabetes, systemic steroids). *Candida* intertrigo usually presents with erythematous plaques and erosions with satellite papules or pustules that can occur in the axillae, genital areas, web spaces of the fingers/toes, and skin folds.

(Choice B) Molluscum bodies indicate molluscum contagiosum, which is caused by a DNA poxvirus. Patients can develop single or multiple lesions that are smooth, 2-6 mm wide, whitish or skin-colored, and firm, and appear as pearly papules often with central umbilication. However, molluscum contagiosum does not typically involve the palms and soles.

(Choice C) Multinucleated giant cells can indicate herpes infections such as shingles, which typically presents as painful vesicles in a dermatomal distribution. This patient's diffuse involvement makes this less likely.

(Choice D) Necrotic keratinocytes in the epidermis suggest Stevens-Johnson syndrome, a severe reaction that occurs 1-3 weeks after an infection (eg, **cytomegalovirus,** *Mycoplasma*) or drug exposure. Patients usually develop high fever, skin pain, mucosal erosions, and skin detachment. However, it typically does not involve the palms and soles. In addition, this patient has no evidence of skin detachment.

Educational objective:

Scabies is a highly contagious disease that presents with an intensely pruritic rash (usually worse at night) in the flexor surfaces of the wrist

above.

(Choice A) Budding yeast indicates *Candida* infection, which most commonly occurs in skin folds with increased moisture and friction. Risk factors include obesity or conditions that interfere with the immune system (eg, diabetes, systemic steroids). *Candida* intertrigo usually presents with erythematous plaques and erosions with satellite papules or pustules that can occur in the axillae, genital areas, web spaces of the fingers/toes, and skin folds.

(Choice B) Molluscum bodies indicate molluscum contagiosum, which is caused by a DNA poxvirus. Patients can develop single or multiple lesions that are smooth, 2-6 mm wide, whitish or skin-colored, and firm, and appear as pearly papules often with central umbilication. However, molluscum contagiosum does not typically involve the palms and soles.

(Choice C) Multinucleated giant cells can indicate herpes infections such as shingles, which typically presents as painful vesicles in a dermatomal distribution. This patient's diffuse involvement makes this less likely.

(Choice D) Necrotic keratinocytes in the epidermis suggest Stevens-Johnson syndrome, a severe reaction that occurs 1-3 weeks after an infection (eg, **cytomegalovirus,** *Mycoplasma*) or drug exposure. Patients usually develop high fever, skin pain, mucosal erosions, and skin detachment. However, it typically does not involve the palms and soles. In addition, this patient has no evidence of skin detachment.

Educational objective:
Scabies is a highly contagious disease that presents with an intensely pruritic rash (usually worse at night) in the flexor surfaces of the wrist, lateral surfaces of the fingers, and the finger webs. Patients usually have excoriations with small, crusted, red papules scattered around the affected areas. Diagnosis is confirmed by skin scrapings from excoriated lesions that show mites, ova, and feces under light microscopy.

References

- Scabies.

Microbiology	Dermatology	Scabies
Subject	System	Topic

Copyright © UWorld. All rights reserved.

Settings

1
2
3
4
5
6
7
8
9
10
11
12
13
14
15
16
17
18
19
20
21
22
23
24
25
26
27
28
29
30

Item 6 of 33
Question Id: 10168

Mark | Previous | Next | Full Screen | Tutorial | Lab Values | Notes | Calculator | Reverse Color | Text Zoom | Settings

above.

Exhibit Display

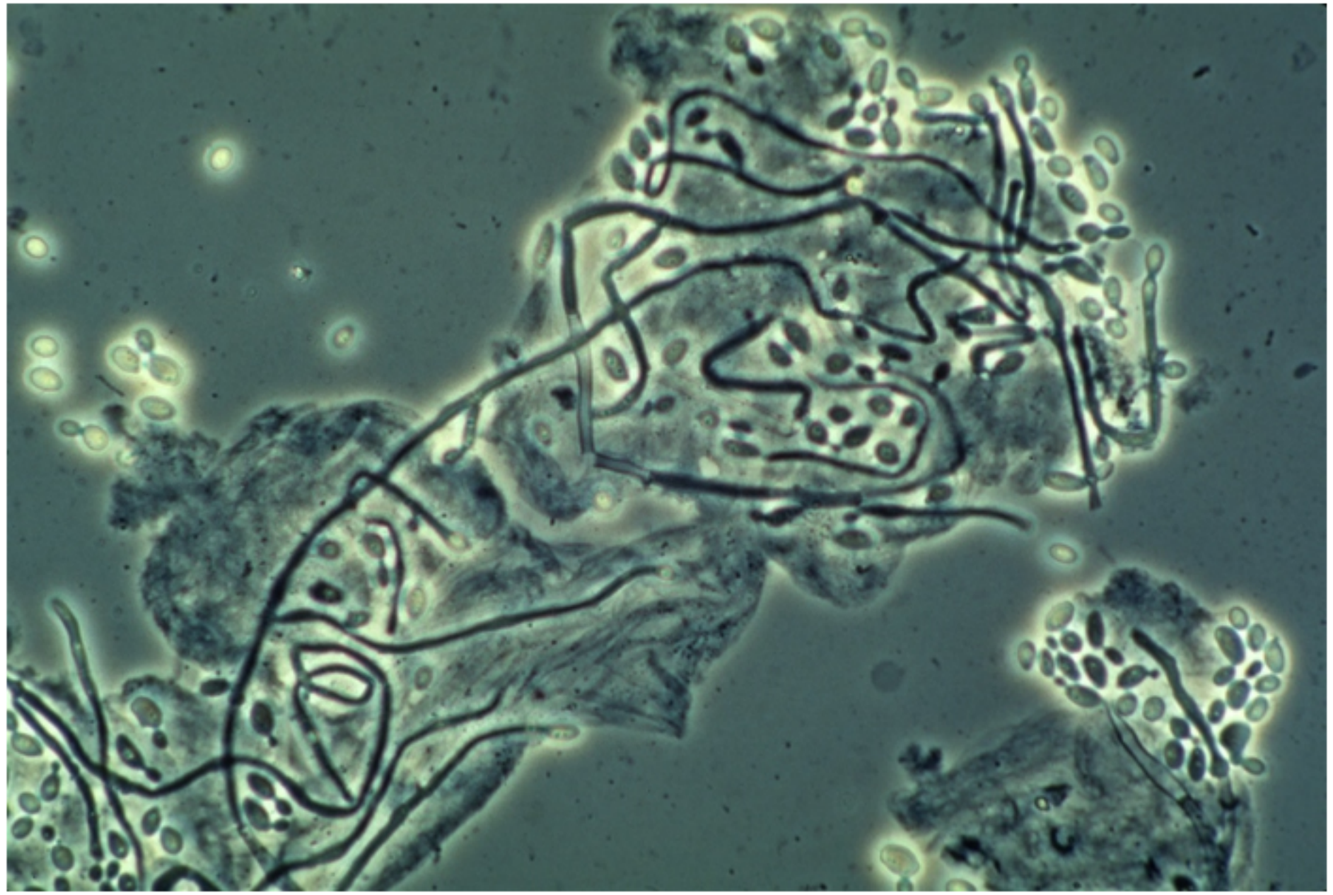

Zoom In | Zoom Out | Reset | Add To New Card | Existing Card

Block Time Remaining: 00:00:20
TUTOR

11 | Feedback | Suspend | End Block

Settings

1
2
3
4
5
6
7
8
9
10
11
12
13
14
15
16
17
18
19
20
21
22
23
24
25
26
27
28
29
30

Item 6 of 33
Question Id: 10168

Mark | Previous | Next | Full Screen | Tutorial | Lab Values | Notes | Calculator | Reverse Color | Text Zoom | Settings

above.

Exhibit Display

Zoom In | Zoom Out | Reset | Add To New Card | Existing Card

Block Time Remaining: 00:00:20
TUTOR

11 | Feedback | Suspend | End Block

Settings

1
2
3
4
5
6
7
8
9
10
11
12
13
14
15
16
17
18
19
20
21
22
23
24
25
26
27
28
29
30

Item 6 of 33
Question Id: 10168

Mark | Previous | Next | Full Screen | Tutorial | Lab Values | Notes | Calculator | Reverse Color | Text Zoom | Settings

above.

(Choice A) Buc
factors include o
with erythematou
fingers/toes, and

(Choice B) Mol
lesions that are s
molluscum conta

(Choice C) Mul
distribution. This

(Choice D) Nec
infection (eg, **cy**
detachment. Ho

Educational ob
Scabies is a high
lateral surfaces o
affected areas.

References

- Scabies.

Microbiology
Subject

Exhibit Display

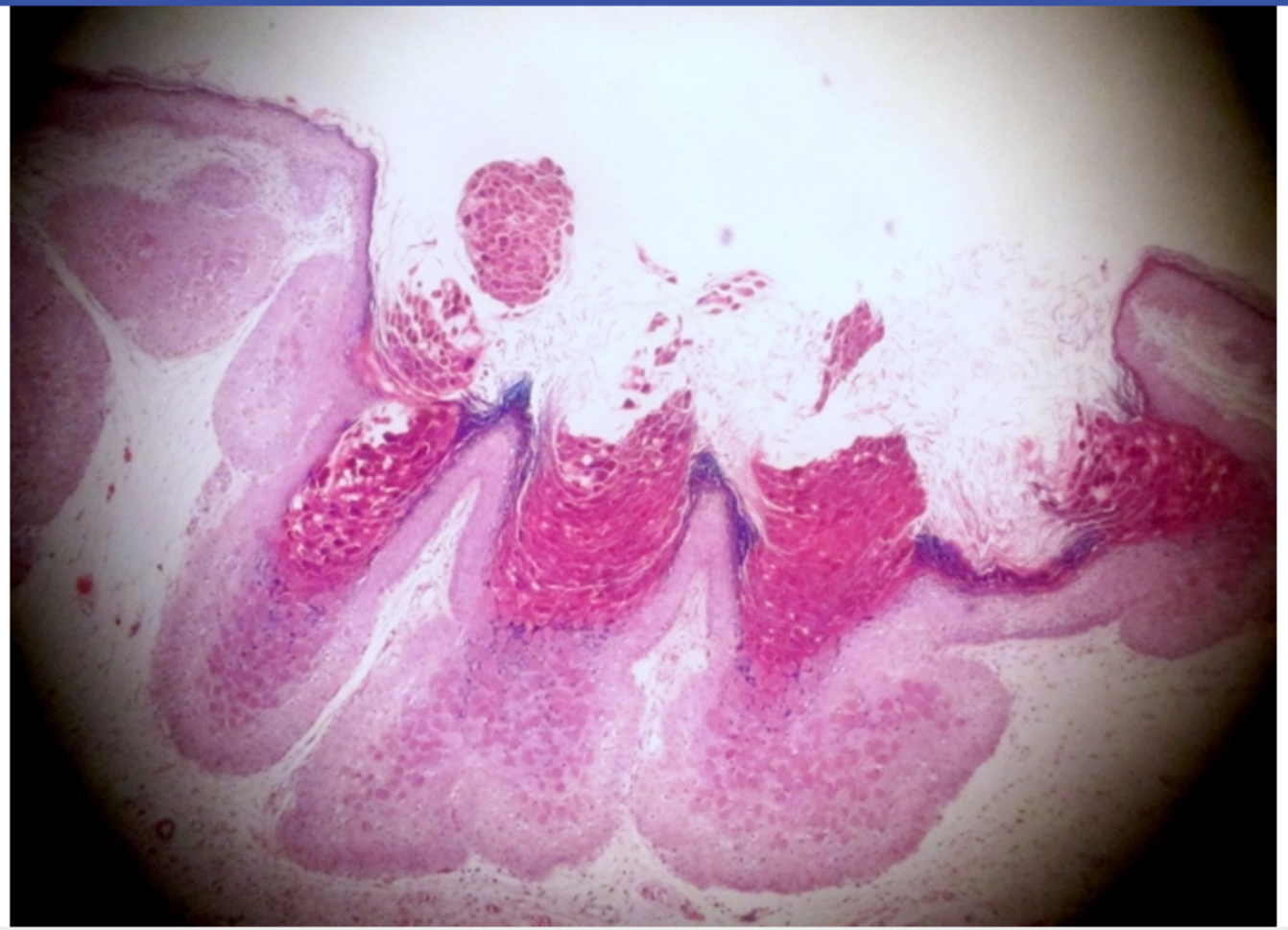

Zoom In | Zoom Out | Reset | Add To New Card | Existing Card

Block Time Remaining: 00:00:20
TUTOR

11 | Feedback | Suspend | End Block

Settings

1
2
3
4
5
6
7
8
9
10
11
12
13
14
15
16
17
18
19
20
21
22
23
24
25
26
27
28
29
30

Item 6 of 33
Question Id: 10168

Mark | Previous | Next | Full Screen | Tutorial | Lab Values | Notes | Calculator | Reverse Color | Text Zoom | Settings

above.

Exhibit Display

Zoom In | Zoom Out | Reset | Add To New Card | Existing Card

Block Time Remaining: 00:00:20
TUTOR

11 | Feedback | Suspend | End Block

Settings

1
2
3
4
5
6
7
8
9
10
11
12
13
14
15
16
17
18
19
20
21
22
23
24
25
26
27
28
29
30

Item 6 of 33
Question Id: 10168

Mark | Previous | Next | Full Screen | Tutorial | Lab Values | Notes | Calculator | Reverse Color | Text Zoom | Settings

above.

Exhibit Display

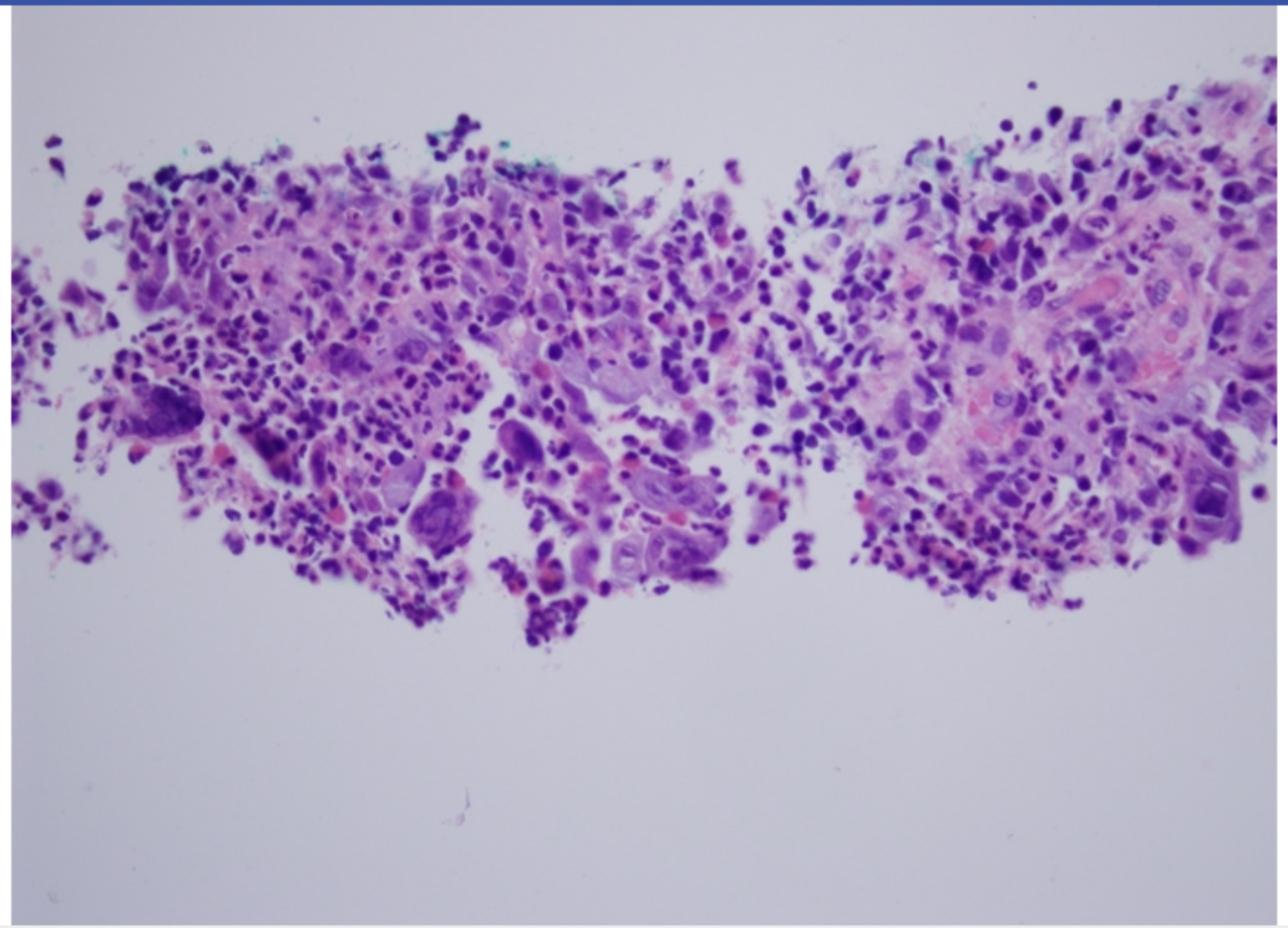

Zoom In | Zoom Out | Reset | Add To New Card | Existing Card

Block Time Remaining: 00:00:20
TUTOR

11 | Feedback | Suspend | End Block

Settings

1
2
3
4
5
6
7
8
9
10
11
12
13
14
15
16
17
18
19
20
21
22
23
24
25
26
27
28
29
30

Item 6 of 33
Question Id: 10168

Mark | Previous | Next | Full Screen | Tutorial | Lab Values | Notes | Calculator | Reverse Color | Text Zoom | Settings

above.

Exhibit Display

Zoom In | Zoom Out | Reset | Add To New Card | Existing Card

Block Time Remaining: 00:00:20
TUTOR

11 | Feedback | Suspend | End Block

Settings

1 2 3 4 5 6 7 8 9 10 11 12 13 14 15 16 17 18 19 20 21 22 23 24 25 26 27 28 29 30

Item 6 of 33
Question Id: 10168

Mark | Previous | Next | Full Screen | Tutorial | Lab Values | Notes | Calculator | Reverse Color | Text Zoom | Settings

above.

Exhibit Display

Zoom In | Zoom Out | Reset | Add To New Card | Existing Card

Block Time Remaining: 00:00:20
TUTOR

11 | Feedback | Suspend | End Block

A 64-year-old man comes to the emergency department due to worsening left lower extremity pain, swelling, and redness over the past 3 days. The patient has had no trauma but reports feeling feverish. Medical history is significant for hypertension and obesity. Temperature is 38 C (100.4 F), blood pressure is 130/86 mm Hg, pulse is 92/min, and respirations are 18/min. BMI is 35 kg/m^2. Physical examination shows diffuse erythema extending up to the left midcalf with indistinct border. There is increased warmth, tenderness, and edema of the left leg. No areas of fluctuation or purulent exudate are present, but the interdigital skin of the feet is macerated and fissured. Laboratory testing shows neutrophilic leukocytosis, and Doppler ultrasonography is negative for deep venous thrombosis. Infection with which of the following organisms is most likely responsible for this patient's current symptoms?

A. Beta-hemolytic streptococci

B. *Candida albicans*

C. *Clostridium perfringens*

D. *Mycobacterium marinum*

E. *Pseudomonas aeruginosa*

F. *Staphylococcus epidermidis*

Submit

A 64-year-old man comes to the emergency department due to worsening left lower extremity pain, swelling, and redness over the past 3 days. The patient has had no trauma but reports feeling feverish. Medical history is significant for hypertension and obesity. Temperature is 38 C (100.4 F), blood pressure is 130/86 mm Hg, pulse is 92/min, and respirations are 18/min. BMI is 35 kg/m^2. Physical examination shows diffuse erythema extending up to the left midcalf with indistinct border. There is increased warmth, tenderness, and edema of the left leg. No areas of fluctuation or purulent exudate are present, but the interdigital skin of the feet is macerated and fissured. Laboratory testing shows neutrophilic leukocytosis, and Doppler ultrasonography is negative for deep venous thrombosis. Infection with which of the following organisms is most likely responsible for this patient's current symptoms?

- ✓ A. Beta-hemolytic streptococci (55%)
- B. *Candida albicans* (3%)
- C. *Clostridium perfringens* (11%)
- D. *Mycobacterium marinum* (3%)
- E. *Pseudomonas aeruginosa* (13%)
- F. *Staphylococcus epidermidis* (12%)

Omitted
Correct answer
A

55%
Answered correctly

02 secs
Time Spent

05/20/2020
Last Updated

Explanation

Cellulitis is an acute bacterial infection of the skin and subcutaneous tissues that is marked by a few days of spreading skin erythema, warmth,

Explanation

Cellulitis is an acute bacterial infection of the skin and subcutaneous tissues that is marked by a few days of spreading skin erythema, warmth, and tenderness. Many patients also have associated fever, leukocytosis, and localized lymphadenopathy. Most cases are driven by disruptions to the skin barrier due to minor trauma, lymphedema, or dermatophytic infection, which allow a portal of entry for bacteria.

Cases of cellulitis are generally divided as follows:

- **Nonpurulent cellulitis** is characterized by skin warmth, edema, and erythema with **no fluctuant nodules**. It is most often caused by **beta-hemolytic streptococci** (groups A, B, C, G, and F); group A streptococcus (*Streptococcus pyogenes*) accounts for the majority of cases.
- **Purulent cellulitis** is characterized by a painful, fluctuant nodule in the dermis or subcutaneus tissue with or without surrounding erythema. The most common cause is *Staphylococcus aureus*; strains that express the virulence factor Panton-Valentine leukocidin are particularly likely to cause skin abscess.

(Choice B) *Candida albicans* is a skin commensal that can cause inflammatory, moist, weeping, erythematous lesions in skin folds. It is not a common cause of acute, spreading cellulitis.

(Choice C) *Clostridium perfringens* causes gas gangrene after traumatic injury (eg, knife wound, surgery) to the skin and soft tissue. It is usually characterized by sudden-onset severe pain, bullous skin lesions, and signs of systemic toxicity/sepsis.

(Choice D) *Mycobacterium marinum* skin infection is usually associated with saltwater exposure and is generally characterized by solitary papules that ulcerate and scar.

(Choice E) *Pseudomonas aeruginosa* skin infections are most common in those who have had exposure to a hot tub ("hot tub folliculitis") or in patients with diabetes mellitus (eg, diabetic foot infection). It is a much less common cause of cellulitis than beta-hemolytic streptococci.

(Choice F) *Staphylococcus epidermis* is a low-virulence skin commensal that rarely causes cellulitis. However, it may occasionally cause bacteremia in patients with intravenous catheters.

Educational objective:
The most common cause of nonpurulent cellulitis is beta-hemolytic streptococci, particularly group A streptococcus. The most common cause of purulent cellulitis is *Staphylococcus aureus*.

- **Purulent cellulitis** is characterized by a painful, fluctuant nodule in the dermis or subcutaneus tissue with or without surrounding erythema. The most common cause is *Staphylococcus aureus*; strains that express the virulence factor Panton-Valentine leukocidin are particularly likely to cause skin abscess.

(Choice B) *Candida albicans* is a skin commensal that can cause inflammatory, moist, weeping, erythematous lesions in skin folds. It is not a common cause of acute, spreading cellulitis.

(Choice C) *Clostridium perfringens* causes gas gangrene after traumatic injury (eg, knife wound, surgery) to the skin and soft tissue. It is usually characterized by sudden-onset severe pain, bullous skin lesions, and signs of systemic toxicity/sepsis.

(Choice D) *Mycobacterium marinum* skin infection is usually associated with saltwater exposure and is generally characterized by solitary papules that ulcerate and scar.

(Choice E) *Pseudomonas aeruginosa* skin infections are most common in those who have had exposure to a hot tub ("hot tub folliculitis") or in patients with diabetes mellitus (eg, diabetic foot infection). It is a much less common cause of cellulitis than beta-hemolytic streptococci.

(Choice F) *Staphylococcus epidermis* is a low-virulence skin commensal that rarely causes cellulitis. However, it may occasionally cause bacteremia in patients with intravenous catheters.

Educational objective:
The most common cause of nonpurulent cellulitis is beta-hemolytic streptococci, particularly group A streptococcus. The most common cause of purulent cellulitis is *Staphylococcus aureus*.

References

- Streptococcus pyogenes: Basic Biology to Clinical Manifestations.

Microbiology	Dermatology	Skin and soft tissue infections
Subject	System	Topic

Copyright © UWorld. All rights reserved.

A 24-year-old woman comes to the office due to copious green vaginal discharge and burning on urination for 3 days. She has a history of a yeast infection 1 year ago, which was treated with over-the-counter medication. She has recently become sexually active with a new partner and occasionally uses condoms. Physical examination shows yellow-green frothy vaginal discharge and diffuse vaginal erythema but no lesions. The uterus is anteverted without cervical motion tenderness. Which of the following is the best test to confirm the diagnosis?

- A. Cervical cytology
- B. Gram stain
- C. pH
- D. Potassium hydroxide testing
- E. Saline microscopy
- F. Urine culture
- G. Viral culture

Submit

A 24-year-old woman comes to the office due to copious green vaginal discharge and burning on urination for 3 days. She has a history of a yeast infection 1 year ago, which was treated with over-the-counter medication. She has recently become sexually active with a new partner and occasionally uses condoms. Physical examination shows yellow-green frothy vaginal discharge and diffuse vaginal erythema but no lesions. The uterus is anteverted without cervical motion tenderness. Which of the following is the best test to confirm the diagnosis?

- A. Cervical cytology (8%)
- B. Gram stain (11%)
- C. pH (8%)
- D. Potassium hydroxide testing (23%)
- ✓ E. Saline microscopy (43%)
- F. Urine culture (4%)
- G. Viral culture (0%)

Omitted
Correct answer
E

43%
Answered correctly

02 secs
Time Spent

02/05/2020
Last Updated

Explanation

Differential diagnosis of vaginitis

Differential diagnosis of vaginitis

Diagnosis	Bacterial vaginosis (*Gardnerella vaginalis*)	Trichomoniasis (*Trichomonas vaginalis*)	Candida vaginitis (*Candida albicans*)
Examination	 • Thin, off-white discharge with fishy odor • No inflammation	 • Thin, yellow-green, malodorous, frothy discharge • Vaginal inflammation	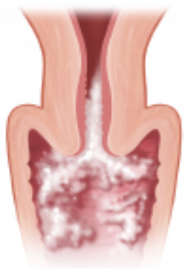 • Thick, "cottage cheese" discharge • Vaginal inflammation
Laboratory findings	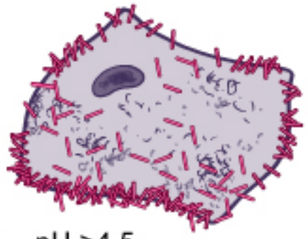 • pH >4.5 • Clue cells • Positive whiff test (amine odor with KOH)	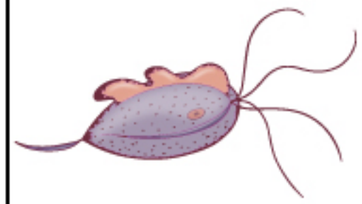 • pH >4.5 • Motile trichomonads	 • Normal pH (3.8-4.5) • Pseudohyphae
Treatment	Metronidazole or clindamycin	Metronidazole; treat sexual partner	Fluconazole

***Trichomonas** vaginalis* is a motile, flagellated protozoan (black arrow) that causes a common **sexually transmitted infection**. Female patients experience **vaginal burning**, itching, urinary discomfort, and yellow or **green vaginal discharge**. In male patients, this organism can cause urethritis, although it is often asymptomatic. Partner treatment is necessary with this infection.

This organism infects the squamous epithelium and causes inflammation in the urogenital tract. An erythematous vaginal mucosa is notable on examination, and cervical punctations may be present (eg. strawberry cervix). The vaginal pH may be elevated. **Saline microscopy** (eg, **wet mount**) of the discharge is the best diagnostic test for identifying trichomonads.

(Choice A) Cervical cytology (also known as Papanicolaou test) is a screening test for cervical cancer. Human papilloma virus (HPV) infection types 16 and 18 cause cervical cancer, which can be prevented by immunization. Pap smear abnormalities and HPV infection are usually asymptomatic.

(Choice B) *Neisseria gonorrhoeae* is a common sexually transmitted infection that may present with purulent vaginal discharge that originates from an inflamed cervix. A Gram stain may show gram-negative diplococci, which are kidney-shaped organisms located in polymorphonuclear leukocytes on microscopy.

(Choice C) pH is elevated in both bacterial vaginosis and trichomonas infection, so pH testing would not be specific. Confounding elevations in pH are caused by presence of semen, blood, cervical mucus, and douching.

(Choice D) Addition of potassium hydroxide (KOH) to the vaginal specimen in cases of bacterial vaginosis releases amines, causing a characteristic odor (eg, positive Whiff test).

(Choice F) Urinary tract infections present with dysuria, urgency, and frequency with no accompanying vaginal discharge. Urine culture identifies the offending organism and is the gold standard for diagnosis.

(Choice G) Herpes simplex virus (particularly type 2) causes painful vesicles in variable stages of resolution and erosions of the vaginal mucosa. Diagnosis can be confirmed by viral culture.

Educational objective:
Trichomonas vaginitis is caused by a motile protozoan which can be seen on wet mount microscopy of vaginal discharge. It presents with yellow-green vaginal discharge and vaginal burning and is sexually transmitted.

asymptomatic.

(Choice B) *Neisseria gonorrhoeae* is a common sexually transmitted infection that may present with purulent vaginal discharge that originates from an inflamed cervix. A Gram stain may show gram-negative diplococci, which are kidney-shaped organisms located in polymorphonuclear leukocytes on microscopy.

(Choice C) pH is elevated in both bacterial vaginosis and trichomonas infection, so pH testing would not be specific. Confounding elevations in pH are caused by presence of semen, blood, cervical mucus, and douching.

(Choice D) Addition of potassium hydroxide (KOH) to the vaginal specimen in cases of bacterial vaginosis releases amines, causing a characteristic odor (eg, positive Whiff test).

(Choice F) Urinary tract infections present with dysuria, urgency, and frequency with no accompanying vaginal discharge. Urine culture identifies the offending organism and is the gold standard for diagnosis.

(Choice G) Herpes simplex virus (particularly type 2) causes painful vesicles in variable stages of resolution and erosions of the vaginal mucosa. Diagnosis can be confirmed by viral culture.

Educational objective:
Trichomonas vaginitis is caused by a motile protozoan which can be seen on wet mount microscopy of vaginal discharge. It presents with yellow-green vaginal discharge and vaginal burning and is sexually transmitted.

References

- ACOG Practice Bulletin. Clinical management guidelines for obstetrician-gynecologists, Number 72, May 2006: Vaginitis.
- Sexually transmitted diseases treatment guidelines, 2015.

Microbiology	Female Reproductive System & Breast	Vulvovaginitis
Subject	System	Topic

Copyright © UWorld. All rights reserved.

Settings

1 2 3 4 5 6 7 8 9 10 11 12 13 14 15 16 17 18 19 20 21 22 23 24 25 26 27 28 29 30

Item 8 of 33
Question Id: 11802

Mark | Previous | Next | Full Screen | Tutorial | Lab Values | Notes | Calculator | Reverse Color | Text Zoom | Settings

Laboratory

Exhibit Display

Zoom In | Zoom Out | Reset | Add To New Card | Existing Card

(Choice D) Addition of potassium hydroxide (KOH) to the vaginal specimen in cases of bacterial vaginosis releases amines, causing a

Block Time Remaining: 00:00:24
TUTOR

4 | Feedback | Suspend | End Block

Laboratory

Exhibit Display

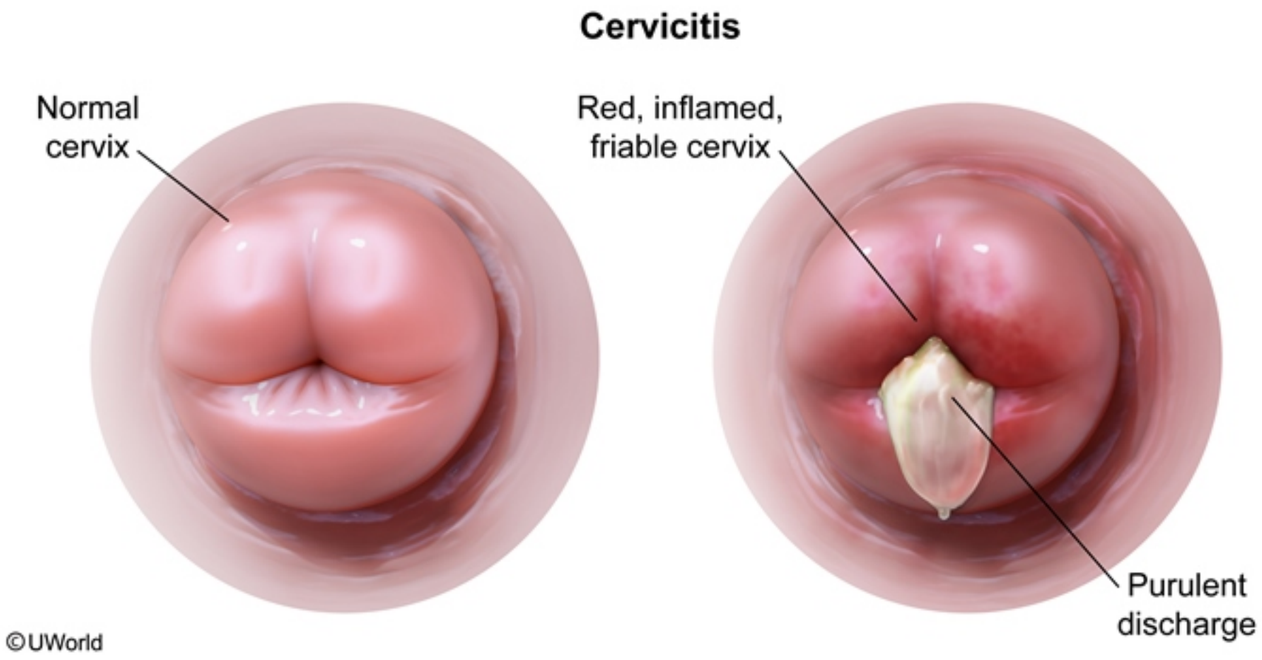

Zoom In | Zoom Out | Reset | Add To New Card | Existing Card

(Choice D) Addition of potassium hydroxide (KOH) to the vaginal specimen in cases of bacterial vaginosis releases amines, causing a

Settings

1
2
3
4
5
6
7
8
9
10
11
12
13
14
15
16
17
18
19
20
21
22
23
24
25
26
27
28
29
30

Item 8 of 33
Question Id: 11802

Mark | Previous | Next | Full Screen | Tutorial | Lab Values | Notes | Calculator | Reverse Color | Text Zoom | Settings

Laboratory

Exhibit Display

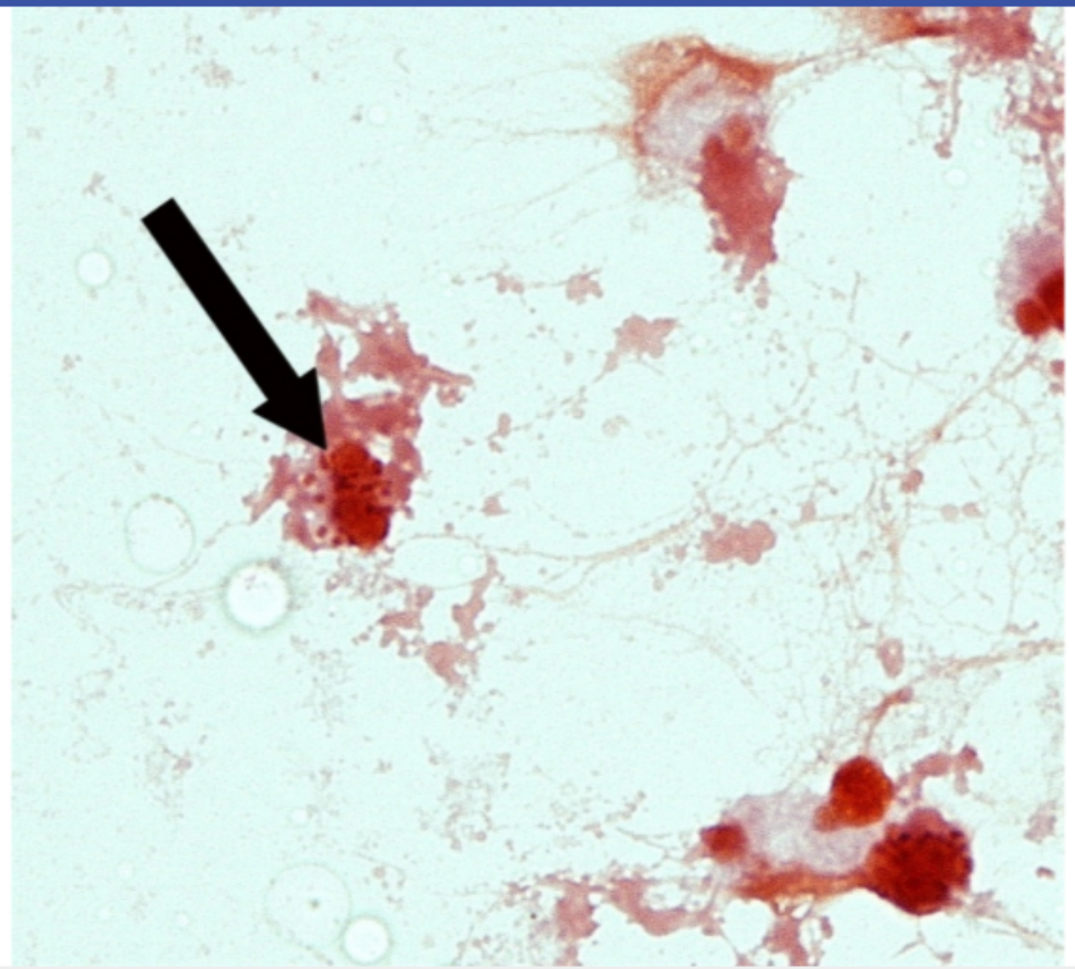

Zoom In | Zoom Out | Reset | Add To New Card | Existing Card

(Choice D) Addition of potassium hydroxide (KOH) to the vaginal specimen in cases of bacterial vaginosis releases amines, causing a

Block Time Remaining: 00:00:24
TUTOR

4 | Feedback | Suspend | End Block

asymptomatic.

(Choice B) *Neisseria gonorrhoeae* is a common sexually transmitted infection that may present with purulent vaginal discharge that originates from an inflamed cervix. A Gram stain may show gram-negative diplococci, which are kidney-shaped organisms located in polymorphonuclear leukocytes on microscopy.

(Choice C) pH is elevated in both bacterial vaginosis and trichomonas infection, so pH testing would not be specific. Confounding elevations in pH are caused by presence of semen, blood, cervical mucus, and douching.

(Choice D) Addition of potassium hydroxide (KOH) to the vaginal specimen in cases of bacterial vaginosis releases amines, causing a characteristic odor (eg, positive Whiff test).

(Choice F) Urinary tract infections present with dysuria, urgency, and frequency with no accompanying vaginal discharge. Urine culture identifies the offending organism and is the gold standard for diagnosis.

(Choice G) Herpes simplex virus (particularly type 2) causes painful vesicles in variable stages of resolution and erosions of the vaginal mucosa. Diagnosis can be confirmed by viral culture.

Educational objective:
Trichomonas vaginitis is caused by a motile protozoan which can be seen on wet mount microscopy of vaginal discharge. It presents with yellow-green vaginal discharge and vaginal burning and is sexually transmitted.

References

- ACOG Practice Bulletin. Clinical management guidelines for obstetrician-gynecologists, Number 72, May 2006: Vaginitis.
- Sexually transmitted diseases treatment guidelines, 2015.

Microbiology	Female Reproductive System & Breast	Vulvovaginitis
Subject	System	Topic

Copyright © UWorld. All rights reserved.

A 24-year-old obese woman comes to the office due to spotting after vaginal intercourse. She also has some yellow vaginal discharge. The patient has taken oral contraceptive pills for the past 3 years and no other medications. Her paternal grandmother was diagnosed with cervical cancer at age 67. The patient's BMI is 35 kg/m^2. On examination, the abdomen is soft and nontender. Speculum examination reveals purulent discharge from the cervical os. The cervix is friable. There is no cervical motion tenderness on bimanual examination and the adnexa are nontender. Microscopy of the discharge demonstrates abundant neutrophils, and nucleic acid amplification testing is positive. If left untreated, the patient's condition could lead to which of the following complications?

A. Cervical cancer

B. Cervical insufficiency

C. Endometrial hyperplasia

D. Infertility

E. Ovarian cancer

Submit

A 24-year-old obese woman comes to the office due to spotting after vaginal intercourse. She also has some yellow vaginal discharge. The patient has taken oral contraceptive pills for the past 3 years and no other medications. Her paternal grandmother was diagnosed with cervical cancer at age 67. The patient's BMI is 35 kg/m^2. On examination, the abdomen is soft and nontender. Speculum examination reveals purulent discharge from the cervical os. The cervix is friable. There is no cervical motion tenderness on bimanual examination and the adnexa are nontender. Microscopy of the discharge demonstrates abundant neutrophils, and nucleic acid amplification testing is positive. If left untreated, the patient's condition could lead to which of the following complications?

- A. Cervical cancer (17%)
- B. Cervical insufficiency (2%)
- C. Endometrial hyperplasia (2%)
- ✓ D. Infertility (76%)
- E. Ovarian cancer (0%)

Omitted
Correct answer
D

76%
Answered correctly

02 secs
Time Spent

05/09/2020
Last Updated

Explanation

Gonococcal cervicitis	

Gonococcal cervicitis	
Clinical features	• Purulent or mucopurulent discharge • Friable cervix with easy bleeding (eg, intermenstrual or postcoital bleeding)
Diagnosis	Nucleic acid amplification testing
Empiric treatment	3rd-generation cephalosporin PLUS Azithromycin or doxycycline

©UWorld

This patient has an **endocervical infection** (cervicitis), which is classically **asymptomatic** and detected by pelvic examination and **nucleic acid amplification testing**. When symptomatic, it presents with a mucopurulent discharge or intermenstrual or post-coital spotting. ***Neisseria gonorrhoeae*** and ***Chlamydia trachomatis*** are the most common pathogens, and untreated infection can ascend to the upper genital tract, resulting in **pelvic inflammatory disease (PID)**.

Treatment with **azithromycin and ceftriaxone** provides coverage of both organisms and prevents the progression of infection to the uterus and fallopian tubes. Up to 20% of PID cases can result in tubal factor **infertility** due to permanent **scarring of the fallopian tubes** from salpingitis. PID also increases the risk for future ectopic pregnancies.

(Choices A and B) Gonococcal and chlamydial infections are not risk factors for cervical cancer. Family history is also not a risk factor for cervical cancer. However, infection with human papillomavirus strains 16 and 18 predisposes to cervical dysplasia and malignant transformation. High-grade cervical lesions require excision before they progress to cancer, but these procedures can cause cervical insufficiency and preterm labor.

(Choice C) Endometrial hyperplasia presents as dysfunctional uterine bleeding. Elevated estrogen without opposition by progesterone stimulates

amplification testing. When symptomatic, it presents with a mucopurulent discharge or intermenstrual or post-coital spotting. ***Neisseria gonorrhoeae*** and ***Chlamydia trachomatis*** are the most common pathogens, and untreated infection can ascend to the upper genital tract, resulting in **pelvic inflammatory disease (PID)**.

Treatment with **azithromycin and ceftriaxone** provides coverage of both organisms and prevents the progression of infection to the uterus and fallopian tubes. Up to 20% of PID cases can result in tubal factor **infertility** due to permanent **scarring of the fallopian tubes** from salpingitis. PID also increases the risk for future ectopic pregnancies.

(Choices A and B) Gonococcal and chlamydial infections are not risk factors for cervical cancer. Family history is also not a risk factor for cervical cancer. However, infection with human papillomavirus strains 16 and 18 predisposes to cervical dysplasia and malignant transformation. High-grade cervical lesions require excision before they progress to cancer, but these procedures can cause cervical insufficiency and preterm labor.

(Choice C) Endometrial hyperplasia presents as dysfunctional uterine bleeding. Elevated estrogen without opposition by progesterone stimulates growth of the uterine lining. Obesity is a risk factor for endometrial hyperplasia due to excess aromatization of androgens to estrogen in the adipose tissue.

(Choice E) Use of combination oral contraceptive pills decreases ovarian cancer risk. Cervicitis is not a risk factor for ovarian cancer.

Educational objective:
Neisseria gonorrhoeae and *Chlamydia trachomatis* cause mucopurulent cervicitis, which can progress to pelvic inflammatory disease (PID) if untreated. PID can cause scarring of the fallopian tubes, leading to ectopic pregnancy and infertility.

References

- Sexually transmitted diseases treatment guidelines, 2015.

Microbiology	Female Reproductive System & Breast	Cervicitis
Subject	System	Topic

Copyright © UWorld. All rights reserved.

A 35-year-old woman comes to the emergency department due to an itchy rash that appeared earlier this morning. She recently returned from a family vacation at a resort in Cancun. Two days ago, the patient's husband developed similar symptoms. The patient has no significant past medical history and takes no medications. She has no known allergies. Her temperature is 37.6 C (99.7 F). On examination, there is a diffuse, pruritic, papulopustular rash that is most noticeable on the trunk and extremities. Microbiologic analysis of a pustular fluid sample demonstrates oxidase-positive gram-negative rods that produce pigment on culture medium. Which of the following is the most likely source of this patient's infection?

A. Food

B. Human contact

C. Insects

D. Pets

E. Pool water

F. Soil

Submit

A 35-year-old woman comes to the emergency department due to an itchy rash that appeared earlier this morning. She recently returned from a family vacation at a resort in Cancun. Two days ago, the patient's husband developed similar symptoms. The patient has no significant past medical history and takes no medications. She has no known allergies. Her temperature is 37.6 C (99.7 F). On examination, there is a diffuse, pruritic, papulopustular rash that is most noticeable on the trunk and extremities. Microbiologic analysis of a pustular fluid sample demonstrates oxidase-positive gram-negative rods that produce pigment on culture medium. Which of the following is the most likely source of this patient's infection?

- A. Food (6%)
- B. Human contact (5%)
- C. Insects (5%)
- D. Pets (1%)
- ✓ E. Pool water (77%)
- F. Soil (3%)

Omitted
Correct answer
E

77%
Answered correctly

01 sec
Time Spent

04/18/2020
Last Updated

Explanation

The clinical syndrome described is consistent with "**hot tub folliculitis**," a superficial pseudomonal infection of the hair follicle. This condition, characterized by a pruritic, papulopustular rash, is most commonly seen with outbreaks from public or hotel swimming pools or hot tubs where the

Correct answer
E

Answered correctly

Time Spent

Last Updated

Explanation

The clinical syndrome described is consistent with "**hot tub folliculitis**," a superficial pseudomonal infection of the hair follicle. This condition, characterized by a pruritic, papulopustular rash, is most commonly seen with outbreaks from public or hotel swimming pools or hot tubs where the chemicals in the **pool water** have not been maintained at appropriate concentrations, thereby allowing ***Pseudomonas aeruginosa*** proliferation.

P aeruginosa is ubiquitous in nature. Many *P aeruginosa* infections often begin with exposure to a **water** source or creation of a moist environment (ie, swimmer's ear, hot tub folliculitis, burn wound). *P aeruginosa* is a motile **gram-negative rod** that is **oxidase**-positive, produces green pigment (**pyocyanin**, pyoverdin) during culture, and is nearly always implicated in "hot tub folliculitis."

(Choices A, B, and C) Scabies can be transmitted by human contact but is due to a mite. *P aeruginosa* is not transmitted by food or insects.

(Choice D) Cat scratch disease is due to the oxidase-negative gram-negative *Bartonella henselae* and can present as vesicular, erythematous, or papular lesions localized to the site of primary inoculation.

(Choice F) Although *P aeruginosa* grows in soil, the most likely source of this patient's infection is exposure to water.

Educational objective:
"Hot tub folliculitis" is a superficial and self-limited *Pseudomonas aeruginosa* infection of the hair follicles that tends to occur in minor outbreaks following exposure to a pool or spa in which the chemicals have not been maintained at appropriate concentrations. *Pseudomonas* are gram-negative, oxidase-positive, nonlactose-fermenting, motile rods that produce green pigment.

Microbiology	Dermatology	Skin and soft tissue infections
Subject	System	Topic

Copyright © UWorld. All rights reserved.

Settings

1
2
3
4
5
6
7
8
9
10
11
12
13
14
15
16
17
18
19
20
21
22
23
24
25
26
27
28
29
30

Item 10 of 33
Question Id: 974

Mark | Previous | Next | Full Screen | Tutorial | Lab Values | Notes | Calculator | Reverse Color | Text Zoom | Settings

Correct answer | Answered correctly | Time Spent | Last Updated

Exhibit Display

Zoom In | Zoom Out | Reset | Add To New Card | Existing Card

Block Time Remaining: 00:00:27
TUTOR

3 | Feedback | Suspend | End Block

An infant born to a 27-year-old immigrant is evaluated for hearing loss. Physical examination demonstrates white pupils and a continuous machinery murmur over the left infraclavicular area. Which of the following preconception interventions would have most likely prevented this infant's condition?

- A. Live attenuated vaccine
- B. Viral component vaccine
- C. Killed vaccine
- D. Toxoid vaccine
- E. Viral enzyme inhibitor drug
- F. Cellular receptor inhibitor drug
- G. Interferons
- H. Prenatal vitamins

Submit

An infant born to a 27-year-old immigrant is evaluated for hearing loss. Physical examination demonstrates white pupils and a continuous machinery murmur over the left infraclavicular area. Which of the following preconception interventions would have most likely prevented this infant's condition?

- ✓ A. Live attenuated vaccine (57%)
- B. Viral component vaccine (6%)
- C. Killed vaccine (16%)
- D. Toxoid vaccine (4%)
- E. Viral enzyme inhibitor drug (5%)
- F. Cellular receptor inhibitor drug (2%)
- G. Interferons (2%)
- H. Prenatal vitamins (4%)

Omitted
Correct answer
A

57%
Answered correctly

02 secs
Time Spent

02/03/2020
Last Updated

Explanation

The congenital rubella syndrome is predominantly characterized by neonatal defects of the head (microcephaly, mental retardation), eyes (cataracts), ears (deafness), and heart/cardiovascular system (patent ductus arteriosus, peripheral pulmonic stenosis). The most classic clinical

The congenital rubella syndrome is predominantly characterized by neonatal defects of the head (microcephaly, mental retardation), eyes (cataracts), ears (deafness), and heart/cardiovascular system (patent ductus arteriosus, peripheral pulmonic stenosis). The most classic clinical triad of congenital rubella includes congenital cataracts (white pupils), sensory-neural deafness, and patent ductus arteriosus. Live attenuated rubella virus vaccine is currently recommended not only for children at 12-15 months and again at 4-6 years of age, but also in non-pregnant women of childbearing age who lack serum antibody against rubella. At the time of vaccination, women are strongly advised to avoid pregnancy for the next four weeks. This vaccination policy has markedly decreased the incidence of congenital rubella.

(Choices B and C) A viral component or killed vaccine is frequently less effective than a live attenuated vaccine. The viral component or killed vaccines tend to induce only humoral immunity, whereas the live attenuated vaccines induce both humoral and cell-mediated immunity. One risk with the live vaccines is the potential for reversion to virulence. Hepatitis A and rabies vaccines are examples of killed vaccines, whereas measles, mumps, and rubella vaccines are examples of live vaccines.

(Choice D) A toxoid may be prepared by treatment of the toxin with formalin or heat. The toxoid can then induce humoral immunity against the toxin without producing serious toxic effects in the vaccine. Because the pathogenesis of rubella infection is not predominantly mediated by a viral toxin, toxoid is ineffective for this disease.

(Choice E) Reverse transcriptase and protease inhibitors are used for HIV infection.

(Choice F) Enfuvirtide is a fusion inhibitor approved for HIV infection. No drugs are available for the treatment of rubella at this time.

(Choice G) Leukocyte IFN-α is a glycoprotein that inhibits various stages of viral RNA and DNA synthesis. It is currently approved for the treatment of hepatitis B and C virus infection, hairy cell leukemia, condyloma acuminatum, and Kaposi's sarcoma. It is not effective in the treatment of rubella infection.

Educational Objective:
The congenital rubella syndrome is predominantly characterized by neonatal defects of the head (microcephaly, mental retardation), eyes (cataracts), ears (deafness), and heart/cardiovascular system (patent ductus arteriosus, peripheral pulmonic stenosis). To decrease the incidence of this syndrome, the CDC currently recommends the vaccination of children and non-pregnant females of childbearing age with live, attenuated rubella virus vaccine.

women of childbearing age who lack serum antibody against rubella. At the time of vaccination, women are strongly advised to avoid pregnancy for the next four weeks. This vaccination policy has markedly decreased the incidence of congenital rubella.

(Choices B and C) A viral component or killed vaccine is frequently less effective than a live attenuated vaccine. The viral component or killed vaccines tend to induce only humoral immunity, whereas the live attenuated vaccines induce both humoral and cell-mediated immunity. One risk with the live vaccines is the potential for reversion to virulence. Hepatitis A and rabies vaccines are examples of killed vaccines, whereas measles, mumps, and rubella vaccines are examples of live vaccines.

(Choice D) A toxoid may be prepared by treatment of the toxin with formalin or heat. The toxoid can then induce humoral immunity against the toxin without producing serious toxic effects in the vaccine. Because the pathogenesis of rubella infection is not predominantly mediated by a viral toxin, toxoid is ineffective for this disease.

(Choice E) Reverse transcriptase and protease inhibitors are used for HIV infection.

(Choice F) Enfuvirtide is a fusion inhibitor approved for HIV infection. No drugs are available for the treatment of rubella at this time.

(Choice G) Leukocyte IFN-α is a glycoprotein that inhibits various stages of viral RNA and DNA synthesis. It is currently approved for the treatment of hepatitis B and C virus infection, hairy cell leukemia, condyloma acuminatum, and Kaposi's sarcoma. It is not effective in the treatment of rubella infection.

Educational Objective:
The congenital rubella syndrome is predominantly characterized by neonatal defects of the head (microcephaly, mental retardation), eyes (cataracts), ears (deafness), and heart/cardiovascular system (patent ductus arteriosus, peripheral pulmonic stenosis). To decrease the incidence of this syndrome, the CDC currently recommends the vaccination of children and non-pregnant females of childbearing age with live, attenuated rubella virus vaccine.

Microbiology	Pregnancy, Childbirth & Puerperium	Rubella
Subject	System	Topic

Copyright © UWorld. All rights reserved.

An 8-year-old girl is brought to the office for evaluation of a skin rash on her upper back. The rash is not painful but is mildly pruritic. She has no prior medical conditions, takes no medications, and is up to date with vaccinations. Vital signs are within normal limits. Right scapular area skin examination is shown in the exhibit. The remainder of the examination is normal. Which of the following is the most likely cause of this patient's current condition?

A. Deep tissue invasion by normal skin flora

B. Epidermal damage from excessive sun exposure

C. Immunologic response to bacterial pharyngitis

D. Microbial infection of keratinized structures

E. Proliferation of pathogen transmitted by tick bite

Submit

Settings

1
2
3
4
5
6
7
8
9
10
11
12
13
14
15
16
17
18
19
20
21
22
23
24
25
26
27
28
29
30

Item 12 of 33
Question Id: 15579

Mark | Previous | Next | Full Screen | Tutorial | Lab Values | Notes | Calculator | Reverse Color | Text Zoom | Settings

Exhibit Display

Zoom In | Zoom Out | Reset | Add To New Card | Existing Card

Block Time Remaining: 00:00:33
TUTOR

7 | Feedback | Suspend | End Block

An 8-year-old girl is brought to the office for evaluation of a skin rash on her upper back. The rash is not painful but is mildly pruritic. She has no prior medical conditions, takes no medications, and is up to date with vaccinations. Vital signs are within normal limits. Right scapular area skin examination is shown in the exhibit. The remainder of the examination is normal. Which of the following is the most likely cause of this patient's current condition?

A. Deep tissue invasion by normal skin flora (6%)

B. Epidermal damage from excessive sun exposure (3%)

C. Immunologic response to bacterial pharyngitis (19%)

✓ D. Microbial infection of keratinized structures (65%)

E. Proliferation of pathogen transmitted by tick bite (4%)

Omitted
Correct answer
D

65%
Answered correctly

07 secs
Time Spent

03/02/2020
Last Updated

Explanation

This patient, with a mildly pruritic, polycyclic rash with a raised, scaly border and central clearing, has **tinea corporis**. Patches of tinea corporis are typically round or ovoid but may become confluent to form a "flower petal" shape. Skin contact, especially in warm and humid environments, is a common risk factor, and patients often have concurrent infections in other body areas. Any species of dermatophyte may cause this condition, but *Trichophyton rubrum* is the most frequent culprit.

Dermatophyte infections (eg, tinea corporis, tinea pedis, tinea cruris) infect keratinized matter in the stratum corneum of the **superficial**

This patient, with a mildly pruritic, polycyclic rash with a raised, scaly border and central clearing, has **tinea corporis**. Patches of tinea corporis are typically round or ovoid but may become confluent to form a "flower petal" shape. Skin contact, especially in warm and humid environments, is a common risk factor, and patients often have concurrent infections in other body areas. Any species of dermatophyte may cause this condition, but *Trichophyton rubrum* is the most frequent culprit.

Dermatophyte infections (eg, tinea corporis, tinea pedis, tinea cruris) infect keratinized matter in the stratum corneum of the **superficial epidermis** but do not invade the dermis and subcutaneous tissues. The diagnosis is confirmed with potassium hydroxide (KOH) preparation of skin scrapings, which can show the characteristic segmented hyphae and arthrospores.

(Choice A) Cutaneous candidiasis (eg, intertrigo) is an inflammatory condition involving approximated skin surfaces such as the axillae, groin, inframammary folds, or abdominal folds. *Candida albicans* is a commensal organism that is normally present on the skin and can become invasive if there is disruption in the normal skin barrier.

(Choice B) Sunburn presents with erythema, itching, and pain in sun-exposed areas. Sunburned skin may undergo superficial desquamation (peeling), but this patient's rounded lesions with peripheral scaling are more consistent with tinea corporis.

(Choice C) Patients with untreated streptococcal pharyngitis can develop erythema marginatum, a fleeting pink or red rash with central clearing that can appear, disappear, and reappear within hours. This is a hallmark feature of rheumatic fever and is usually accompanied by other signs such as migratory arthritis, carditis, subcutaneous nodules, and Sydenham chorea.

(Choice E) Acute Lyme disease is characterized by flu-like symptoms and erythema migrans, a slowly spreading erythematous rash with central clearing at the site of the tick bite. Disseminated disease can present with multiple lesions, but the lesions are flat or only slightly raised and the border is indistinct rather than scaly; they often develop a targetoid appearance.

Educational objective:
Tinea corporis presents with round or ovoid lesions with a raised, scaly border and central clearing. *Trichophyton rubrum* is the most common cause and infects keratinized matter in the stratum corneum of the superficial epidermis but does not invade the dermis and subcutaneous tissues.

References

- Mycology – an update. Part 1: dermatomycoses: causative agents, epidemiology and pathogenesis.

Exhibit Display

Layers of the epidermis

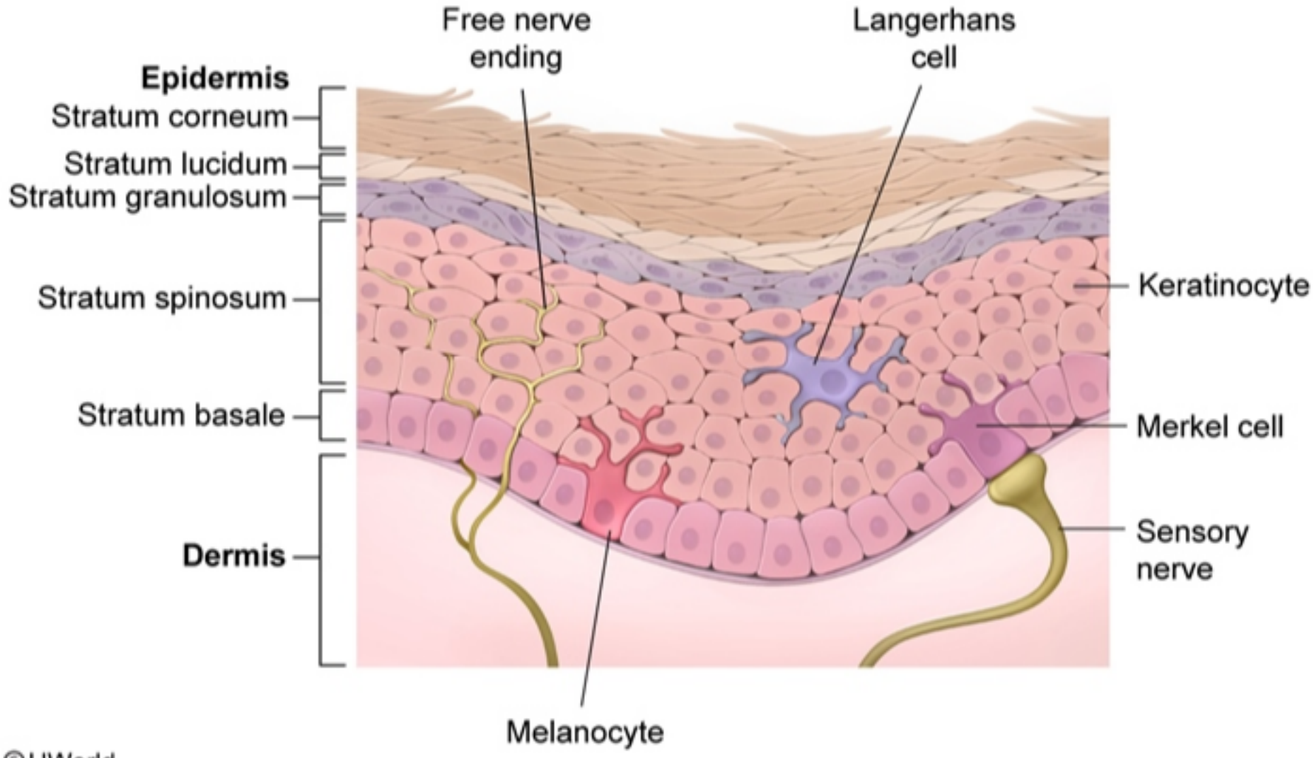

©UWorld

Zoom In | Zoom Out | Reset | Add To New Card | Existing Card

Settings

1
2
3
4
5
6
7
8
9
10
11
12
13
14
15
16
17
18
19
20
21
22
23
24
25
26
27
28
29
30

Item 12 of 33
Question Id: 15579

Mark | Previous | Next | Full Screen | Tutorial | Lab Values | Notes | Calculator | Reverse Color | Text Zoom | Settings

Exhibit Display

Zoom In | Zoom Out | Reset | Add To New Card | Existing Card

Block Time Remaining: 00:00:36
TUTOR

7 | Feedback | Suspend | End Block

Settings

1
2
3
4
5
6
7
8
9
10
11
12
13
14
15
16
17
18
19
20
21
22
23
24
25
26
27
28
29
30

Item 12 of 33
Question Id: 15579

Mark | Previous | Next | Full Screen | Tutorial | Lab Values | Notes | Calculator | Reverse Color | Text Zoom | Settings

Exhibit Display

Zoom In | Zoom Out | Reset | Add To New Card | Existing Card

Block Time Remaining: 00:00:36
TUTOR

7 | Feedback | Suspend | End Block

Settings

1
2
3
4
5
6
7
8
9
10
11
12
13
14
15
16
17
18
19
20
21
22
23
24
25
26
27
28
29
30

Item 12 of 33
Question Id: 15579

Mark | Previous | Next | Full Screen | Tutorial | Lab Values | Notes | Calculator | Reverse Color | Text Zoom | Settings

Exhibit Display

Zoom In | Zoom Out | Reset | Add To New Card | Existing Card

Block Time Remaining: 00:00:36
TUTOR

7 | Feedback | Suspend | End Block

A 29-year-old man is evaluated for 2 weeks of skin rash involving his hands, feet, and scalp. The rash is mildly pruritic and has progressively worsened. The patient has a history of HIV and is not adherent with antiretroviral therapy. Skin examination shows erythematous patches with scales and crusting. Biopsy of the rash shows organisms burrowed in the epidermis, as shown below:

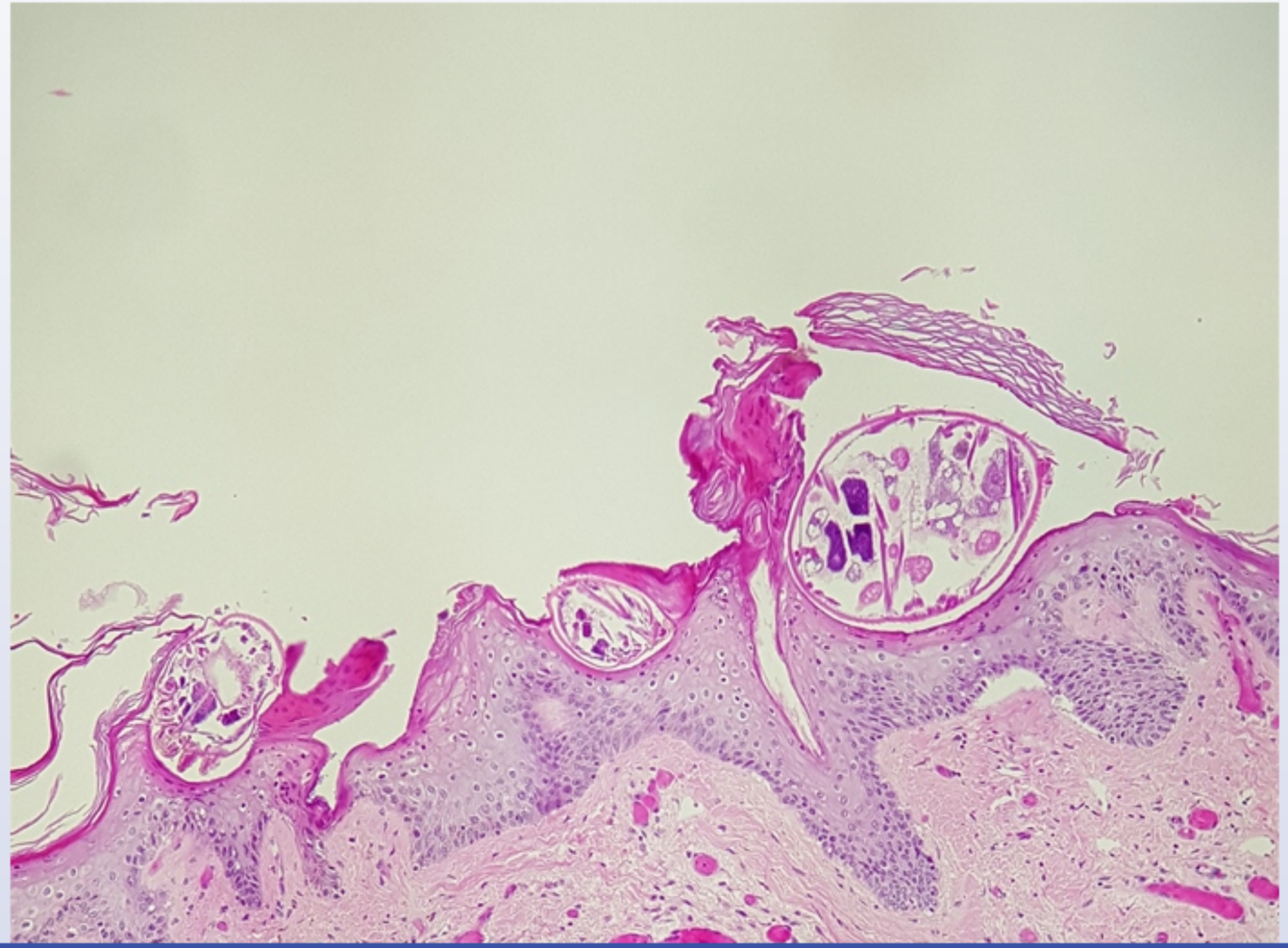

Settings

1
2
3
4
5
6
7
8
9
10
11
12
13
14
15
16
17
18
19
20
21
22
23
24
25
26
27
28
29
30

Item 13 of 33
Question Id: 13911

Mark

Previous

Next

Full Screen

Tutorial

Lab Values

Notes

Calculator

Reverse Color

Text Zoom

Settings

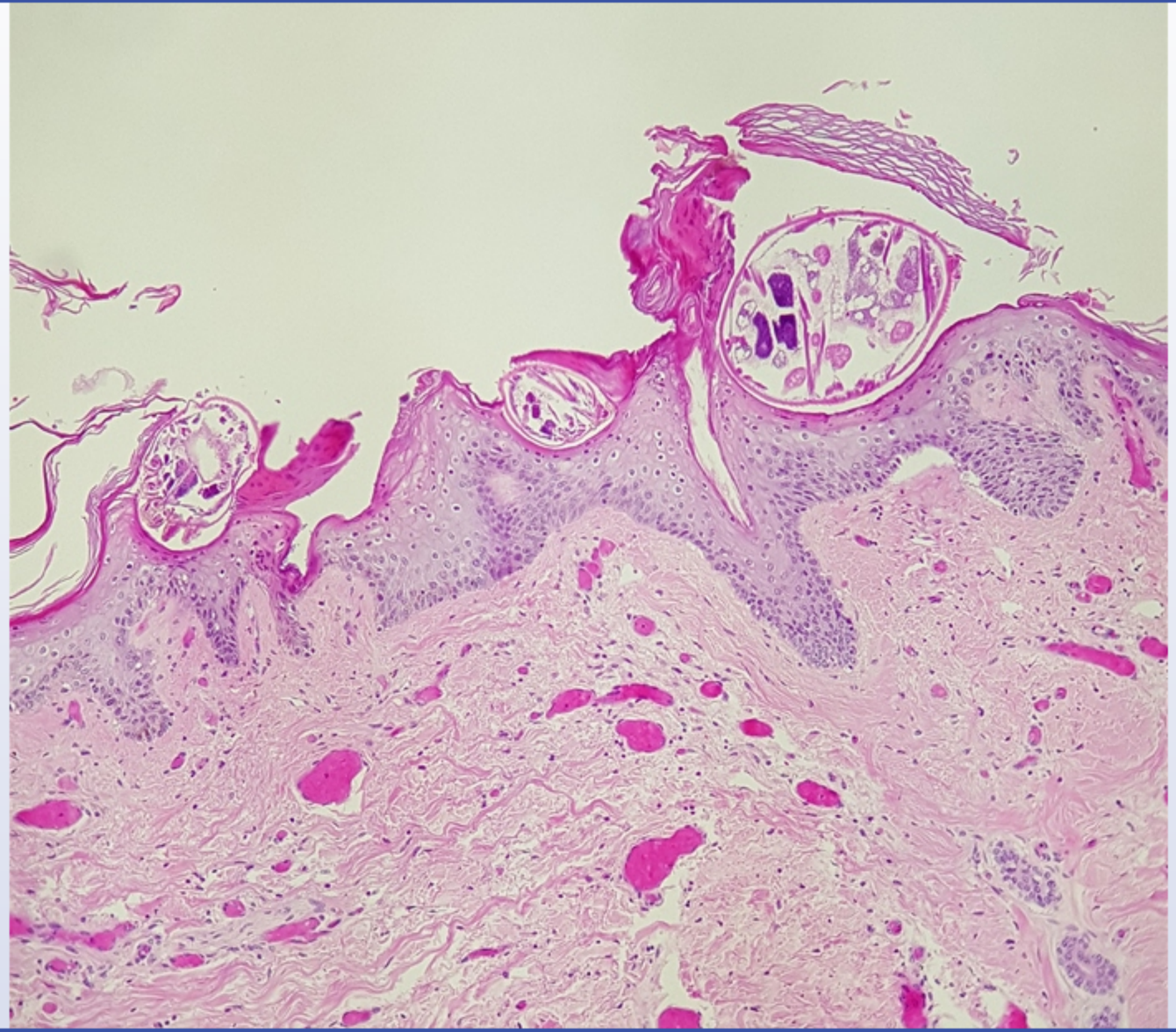

Block Time Remaining: 00:00:40
TUTOR

8

Feedback

Suspend

End Block

Settings

1 2 3 4 5 6 7 8 9 10 11 12 13 14 15 16 17 18 19 20 21 22 23 24 25 26 27 28 29 30

Item 13 of 33
Question Id: 13911

Mark | Previous | Next | Full Screen | Tutorial | Lab Values | Notes | Calculator | Reverse Color | Text Zoom | Settings

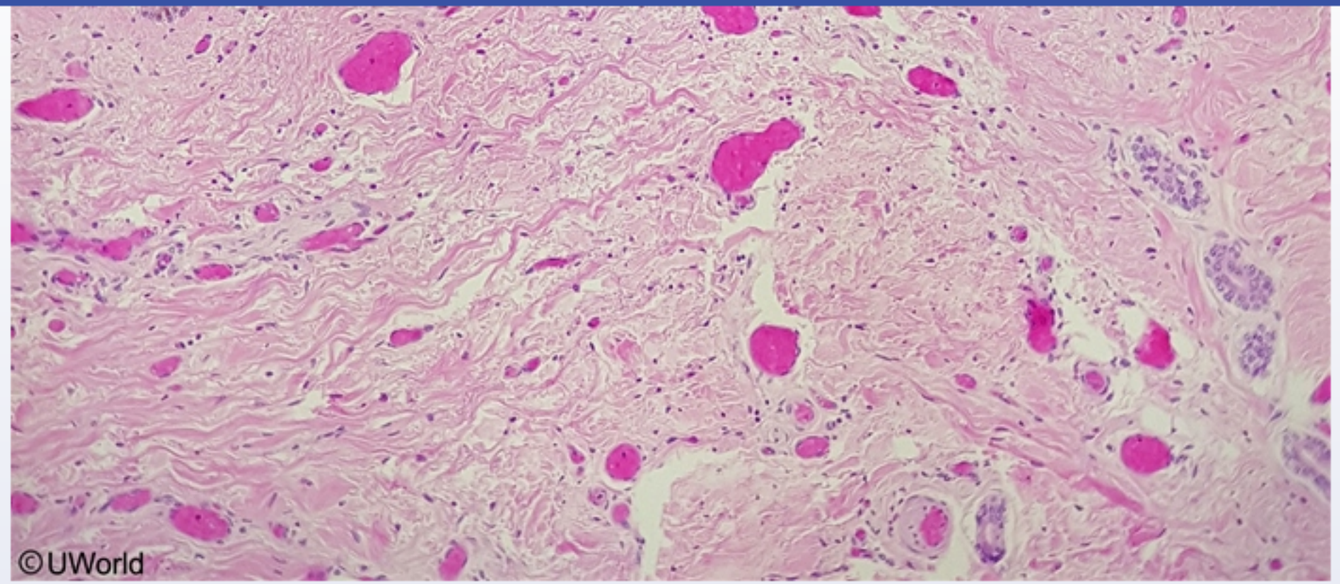

Which of the following is the most appropriate treatment for this patient?

- A. Systemic acyclovir
- B. Systemic terbinafine
- C. Topical glucocorticoid
- D. Topical mupirocin
- E. Topical permethrin

Submit

Block Time Remaining: 00:00:42
TUTOR

8 | Feedback | Suspend | End Block

1 2 3 4 5 6 7 8 9 10 11 12 13 14 15 16 17 18 19 20 21 22 23 24 25 26 27 28 29 30

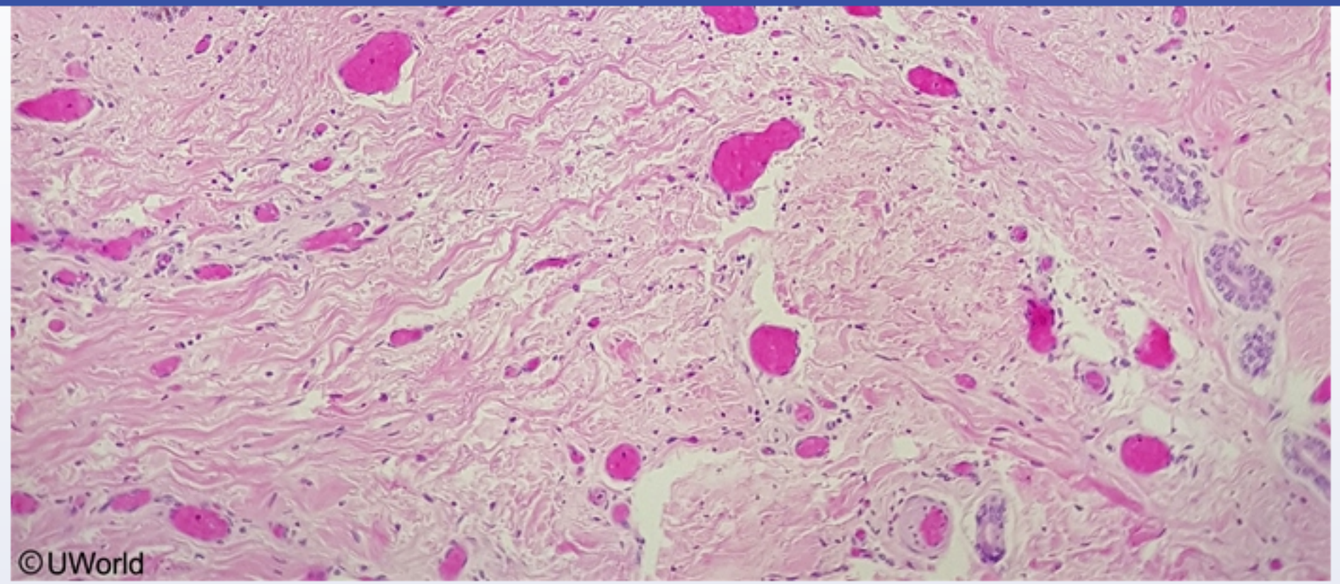

Which of the following is the most appropriate treatment for this patient?

A. Systemic acyclovir (5%)

B. Systemic terbinafine (20%)

C. Topical glucocorticoid (3%)

D. Topical mupirocin (6%)

✓ E. Topical permethrin (63%)

Omitted
Correct answer

63%
Answered correctly

08 secs
Time Spent

01/28/2020
Last Updated

Settings

1
2
3
4
5
6
7
8
9
10
11
12
13
14
15
16
17
18
19
20
21
22
23
24
25
26
27
28
29
30

Item 13 of 33
Question Id: 13911

Mark

Previous

Next

Full Screen

Tutorial

Lab Values

Notes

Calculator

Reverse Color

Text Zoom

Settings

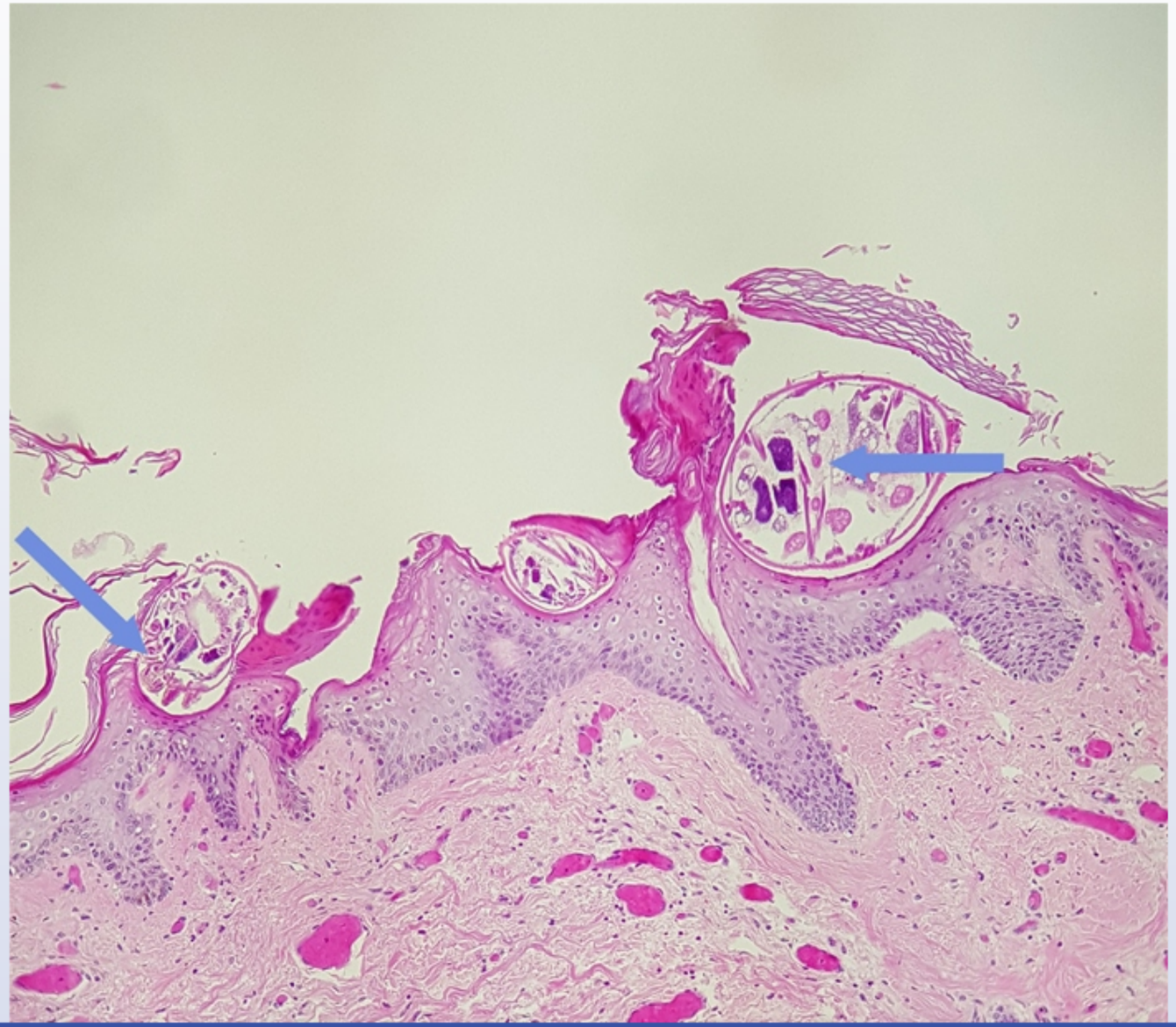

Block Time Remaining: 00:00:44
TUTOR

8

Feedback

Suspend

End Block

Scabies is a skin infection caused by the human mite *Sarcoptes scabiei*. Transmission occurs from prolonged skin-to-skin contact with an infected individual but may occasionally occur due to contact with contaminated fomites (eg, bedsheets, clothing). Mites burrow under the epidermis and evoke a delayed-type hypersensitivity reaction to mite feces and eggs, which leads to an intensely **pruritic rash**. The mite's internal organs, eggs, and spine can often be seen on histopathology.

Classic scabies is associated with a mild mite burden (10-15 mites). Patients usually have several small erythematous papules on the sides/webs of the fingers, wrists, elbows, axillae, waist, and genitalia. Excoriations and **burrows** (thin, serpiginous red tracks) may be seen. In contrast, patients with impaired cell-mediated immunity (eg, **HIV**) are unable to contain the infection and usually develop crusted scabies, which is associated with thousands or **millions** of mites. These patients often have mild pruritis (because the inflammatory response is muted) and several erythematous patches with scaling and crusting.

Treatment is required to prevent discomfort, transmission, and potential complications (eg, secondary bacterial infection). First-line therapy includes **topical permethrin**, which blocks mite neurotransmission by impairing voltage-gated sodium channels. Permethrin cream is applied from the neck to the soles of the feet and left on for 8-14 hours. Oral **ivermectin**, an antiparasitic agent that binds chloride ion channels in invertebrate nerve and muscle cells, is an alternate medication for classic scabies and is used with permethrin for crusted scabies.

(Choice A) Oral acyclovir is used for human herpes simplex virus outbreaks, which are usually characterized by vesicular lesions on an erythematous base. The orolabial mucosa and genital area are affected most commonly. Histopathology would show an epidermal blister with acantholysis and multinucleated cells.

(Choice B) Oral terbinafine can be used for patients with dermatophytic infections of the skin. Dermatophytes often cause an erythematous scaly rash and erosions. Histopathology typically reveals fungal spores and/or hyphae.

(Choice C) Psoriasis is a chronic inflammatory skin condition that can be treated with topical glucocorticoids. It is usually associated with symmetric, sharply defined skin plaques with overlying scales on the extensor elbows, knees, and scalp. Histopathology generally shows uniform epidermal hyperplasia, hyperkeratosis, and perivascular lymphocytes.

(Choice D) Topical mupirocin can treat *Staphylococcus aureus*, the most common cause of purulent cellulitis. Patients usually have a focal, painful area of nodular fluctuance and surrounding erythema.

associated with thousands or **millions** of mites. These patients often have mild pruritis (because the inflammatory response is muted) and several erythematous patches with scaling and crusting.

Treatment is required to prevent discomfort, transmission, and potential complications (eg, secondary bacterial infection). First-line therapy includes **topical permethrin**, which blocks mite neurotransmission by impairing voltage-gated sodium channels. Permethrin cream is applied from the neck to the soles of the feet and left on for 8-14 hours. Oral **ivermectin**, an antiparasitic agent that binds chloride ion channels in invertebrate nerve and muscle cells, is an alternate medication for classic scabies and is used with permethrin for crusted scabies.

(Choice A) Oral acyclovir is used for human herpes simplex virus outbreaks, which are usually characterized by vesicular lesions on an erythematous base. The orolabial mucosa and genital area are affected most commonly. Histopathology would show an epidermal blister with acantholysis and multinucleated cells.

(Choice B) Oral terbinafine can be used for patients with dermatophytic infections of the skin. Dermatophytes often cause an erythematous scaly rash and erosions. Histopathology typically reveals fungal spores and/or hyphae.

(Choice C) Psoriasis is a chronic inflammatory skin condition that can be treated with topical glucocorticoids. It is usually associated with symmetric, sharply defined skin plaques with overlying scales on the extensor elbows, knees, and scalp. Histopathology generally shows uniform epidermal hyperplasia, hyperkeratosis, and perivascular lymphocytes.

(Choice D) Topical mupirocin can treat *Staphylococcus aureus*, the most common cause of purulent cellulitis. Patients usually have a focal, painful area of nodular fluctuance and surrounding erythema.

Educational objective:
Scabies is a human mite infection associated with a pruritic papular rash with excoriations and burrows. Patients with impaired cell-mediated immunity (eg, HIV) often develop a very high mite burden. Treatment with topical permethrin and/or ivermectin is generally curative.

Microbiology	Dermatology	Scabies
Subject	System	Topic

Copyright © UWorld. All rights reserved.

Settings

1 2 3 4 5 6 7 8 9 10 11 12 13 14 15 16 17 18 19 20 21 22 23 24 25 26 27 28 29 30

Item 13 of 33
Question Id: 13911

Mark | Previous | Next | Full Screen | Tutorial | Lab Values | Notes | Calculator | Reverse Color | Text Zoom | Settings

Exhibit Display

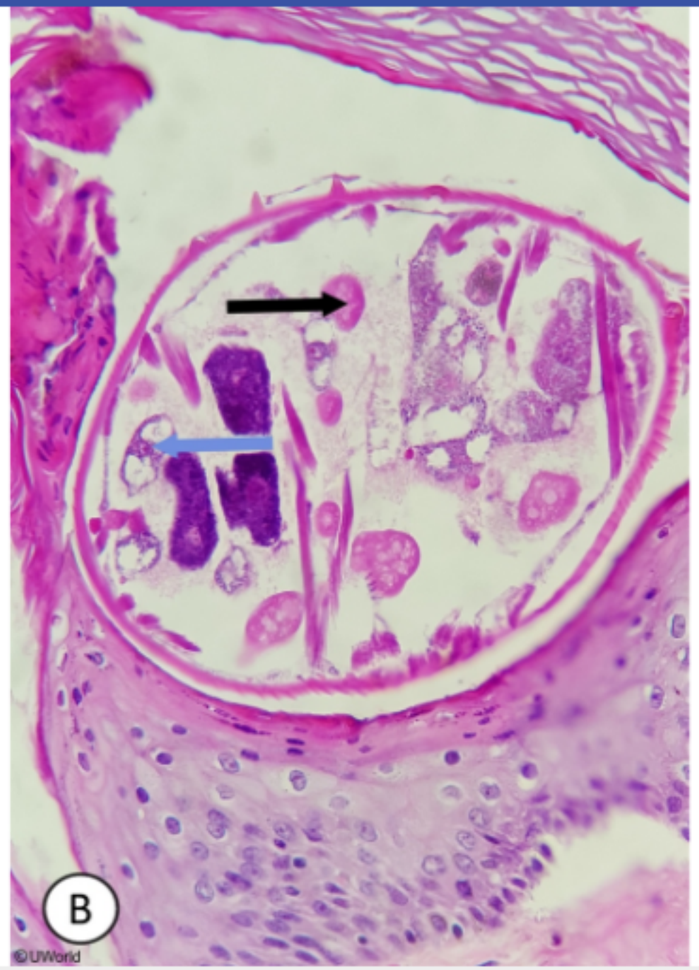

Zoom In | Zoom Out | Reset | Add To New Card | Existing Card

acantholysis and multinucleated cells.

Block Time Remaining: 00:00:44
TUTOR

8 | Feedback | Suspend | End Block

Settings

1 2 3 4 5 6 7 8 9 10 11 12 13 14 15 16 17 18 19 20 21 22 23 24 25 26 27 28 29 30

Item 13 of 33
Question Id: 13911

Mark | Previous | Next | Full Screen | Tutorial | Lab Values | Notes | Calculator | Reverse Color | Text Zoom | Settings

Exhibit Display

Zoom In | Zoom Out | Reset | Add To New Card | Existing Card

(Choice C) Psoriasis is a chronic inflammatory skin condition that can be treated with topical glucocorticoids. It is usually associated with

Block Time Remaining: 00:00:44
TUTOR

8 | Feedback | Suspend | End Block

1 2 3 4 5 6 7 8 9 10 11 12 13 14 15 16 17 18 19 20 21 22 23 24 25 26 27 28 29 30

Classic scabies is associated with a mild mite burden (10-15 mites). Patients usually have several small erythematous papules on the sides/webs

Exhibit Display

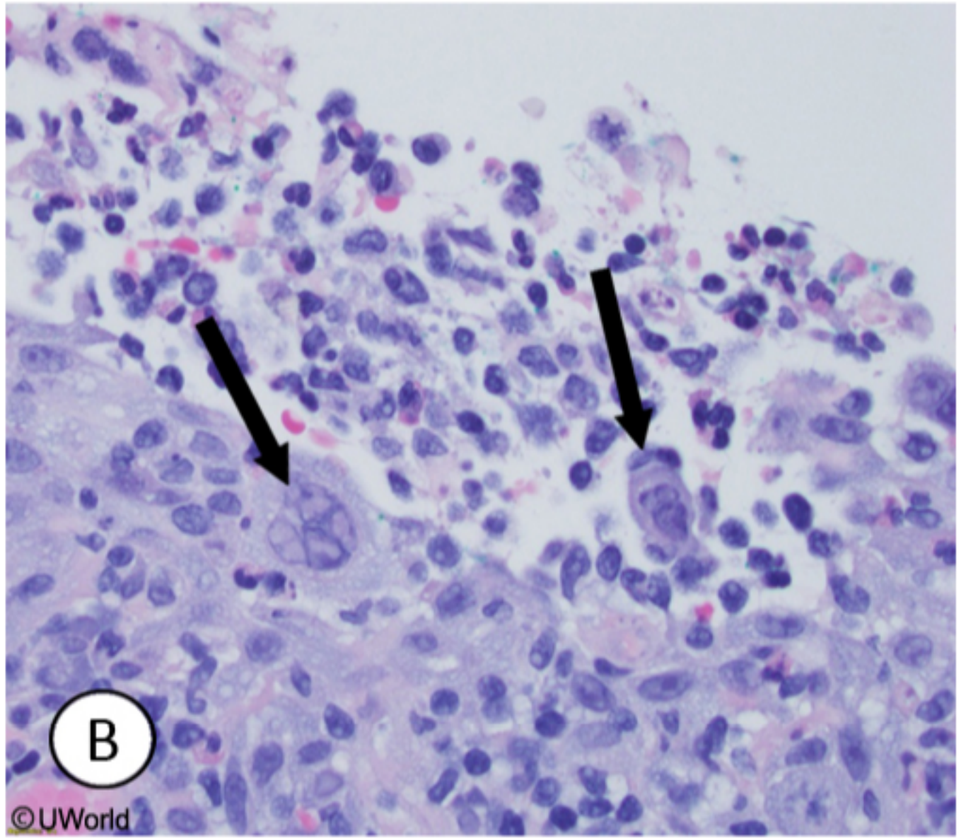

Zoom In | Zoom Out | Reset | Add To New Card | Existing Card

Microbiology Dermatology Scabies

Settings

1 2 3 4 5 6 7 8 9 10 11 12 13 14 15 16 17 18 19 20 21 22 23 24 25 26 27 28 29 30

Item 13 of 33
Question Id: 13911

Mark | Previous | Next | Full Screen | Tutorial | Lab Values | Notes | Calculator | Reverse Color | Text Zoom | Settings

Classic scabies is associated with a mild mite burden (10-15 mites). Patients usually have several small erythematous papules on the sides/webs

Exhibit Display

Zoom In | Zoom Out | Reset | Add To New Card | Existing Card

Microbiology Dermatology Scabies

Block Time Remaining: 00:00:44
TUTOR

8 | Feedback | Suspend | End Block

Settings

1 2 3 4 5 6 7 8 9 10 11 12 13 14 15 16 17 18 19 20 21 22 23 24 25 26 27 28 29 30

Item 13 of 33
Question Id: 13911

Mark | Previous | Next | Full Screen | Tutorial | Lab Values | Notes | Calculator | Reverse Color | Text Zoom | Settings

Classic scabies is associated with a mild mite burden (10-15 mites). Patients usually have several small erythematous papules on the sides/webs

Exhibit Display

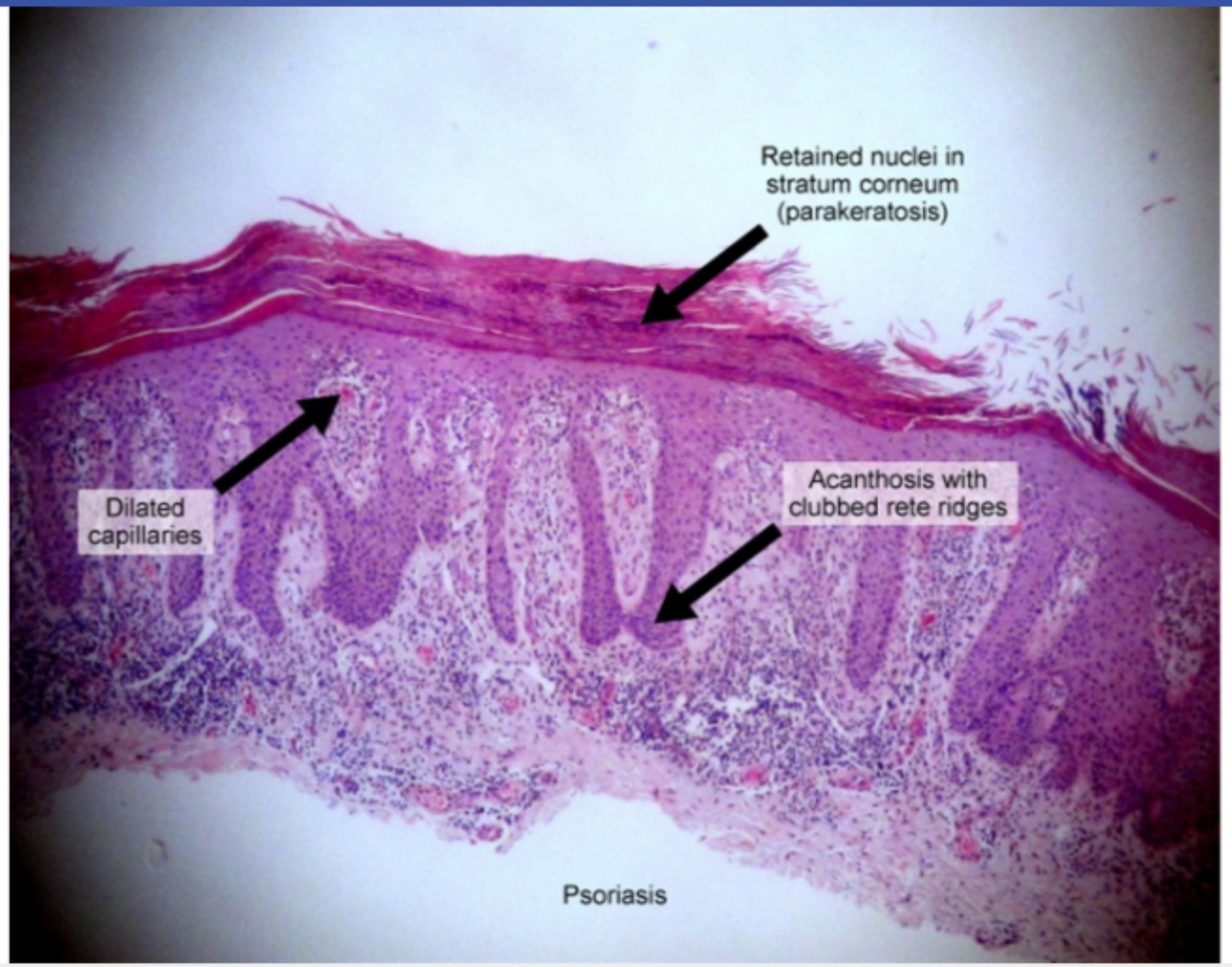

Zoom In | Zoom Out | Reset | Add To New Card | Existing Card

Microbiology Dermatology Scabies

Block Time Remaining: 00:00:44
TUTOR

8 | Feedback | Suspend | End Block

associated with thousands or **millions** of mites. These patients often have mild pruritis (because the inflammatory response is muted) and several erythematous patches with scaling and crusting.

Treatment is required to prevent discomfort, transmission, and potential complications (eg, secondary bacterial infection). First-line therapy includes **topical permethrin**, which blocks mite neurotransmission by impairing voltage-gated sodium channels. Permethrin cream is applied from the neck to the soles of the feet and left on for 8-14 hours. Oral **ivermectin**, an antiparasitic agent that binds chloride ion channels in invertebrate nerve and muscle cells, is an alternate medication for classic scabies and is used with permethrin for crusted scabies.

(Choice A) Oral acyclovir is used for human herpes simplex virus outbreaks, which are usually characterized by vesicular lesions on an erythematous base. The orolabial mucosa and genital area are affected most commonly. Histopathology would show an epidermal blister with acantholysis and multinucleated cells.

(Choice B) Oral terbinafine can be used for patients with dermatophytic infections of the skin. Dermatophytes often cause an erythematous scaly rash and erosions. Histopathology typically reveals fungal spores and/or hyphae.

(Choice C) Psoriasis is a chronic inflammatory skin condition that can be treated with topical glucocorticoids. It is usually associated with symmetric, sharply defined skin plaques with overlying scales on the extensor elbows, knees, and scalp. Histopathology generally shows uniform epidermal hyperplasia, hyperkeratosis, and perivascular lymphocytes.

(Choice D) Topical mupirocin can treat *Staphylococcus aureus*, the most common cause of purulent cellulitis. Patients usually have a focal, painful area of nodular fluctuance and surrounding erythema.

Educational objective:
Scabies is a human mite infection associated with a pruritic papular rash with excoriations and burrows. Patients with impaired cell-mediated immunity (eg, HIV) often develop a very high mite burden. Treatment with topical permethrin and/or ivermectin is generally curative.

Microbiology	Dermatology	Scabies
Subject	System	Topic

Copyright © UWorld. All rights reserved.

A 58-year-old asymptomatic woman comes to the office for a health checkup prior to starting volunteer work at a hospital. She has a history of hypothyroidism and takes levothyroxine. She does not use tobacco, alcohol, or illicit drugs. Her examination findings are unremarkable. During a laboratory test, her white blood cells are incubated with mycobacterial antigens. Compared to the control, a large amount of interferon-gamma is detected in her blood sample. Which of the following cell types is most directly responsible for this finding?

A. B lymphocytes

B. Basophils

C. Eosinophils

D. Monocytes

E. Neutrophils

F. T lymphocytes

Submit

A 58-year-old asymptomatic woman comes to the office for a health checkup prior to starting volunteer work at a hospital. She has a history of hypothyroidism and takes levothyroxine. She does not use tobacco, alcohol, or illicit drugs. Her examination findings are unremarkable. During a laboratory test, her white blood cells are incubated with mycobacterial antigens. Compared to the control, a large amount of interferon-gamma is detected in her blood sample. Which of the following cell types is most directly responsible for this finding?

- A. B lymphocytes (3%)
- B. Basophils (0%)
- C. Eosinophils (0%)
- D. Monocytes (17%)
- E. Neutrophils (4%)
- ✓ F. T lymphocytes (73%)

Omitted
Correct answer
F

73%
Answered correctly

01 sec
Time Spent

07/07/2020
Last Updated

Explanation

Interferon-gamma (IFN-γ) activates macrophages, increases major histocompatibility complex expression, and promotes T helper 1 lymphocyte (Th1) differentiation. It is produced primarily by activated **T lymphocytes** and natural killer cells and is critical in immunity against viral and intracellular bacterial infections. IFN-γ release assays (IGRAs) test for **latent tuberculosis infection** (LTBI) by measuring the response of T lymphocytes when exposed to antigens unique to *Mycobacterium tuberculosis*. Similar to tuberculin skin tests (eg, purified protein derivative),

Interferon-gamma (IFN-γ) activates macrophages, increases major histocompatibility complex expression, and promotes T helper 1 lymphocyte (Th1) differentiation. It is produced primarily by activated **T lymphocytes** and natural killer cells and is critical in immunity against viral and intracellular bacterial infections. IFN-γ release assays (IGRAs) test for **latent tuberculosis infection** (LTBI) by measuring the response of T lymphocytes when exposed to antigens unique to *Mycobacterium tuberculosis*. Similar to tuberculin skin tests (eg, purified protein derivative), IGRAs measure cell-mediated immunity.

IGRAs have comparable sensitivity and specificity to tuberculin skin tests, but advantages include their lack of cross-reactivity to the Bacille Calmette-Guérin (BCG) vaccine and that a follow-up visit is not required. Neither skin tests nor IGRAs can be used to distinguish active tuberculosis from LTBI.

(Choice A) B lymphocytes are the main cell type involved in the humoral immune system and the production of circulating antibodies.

(Choices B and D) Basophils and antigen-presenting cells such as monocyte-derived macrophages interact with T cells to control the immune response but are not directly responsible for IFN-γ release.

(Choices C and E) Eosinophils help eradicate parasitic infections (eg, helminths), whereas neutrophils are involved in the phagocytosis of bacteria and other pathogens.

Educational objective:
Interferon-gamma (IFN-γ) release assays test for latent tuberculosis infection by measuring the amount of IFN-γ released by T lymphocytes when exposed to antigens unique to *Mycobacterium tuberculosis*.

References

- Gamma interferon release assays for detection of Mycobacterium tuberculosis infection.
- Regulation of interferon-gamma during innate and adaptive immune responses.
- Clinical application and limitations of interferon-gamma release assays for the diagnosis of latent tuberculosis infection.

Microbiology	Allergy & Immunology	Tuberculosis
Subject	System	Topic

Interferon gamma (IFN-γ) activates macrophages, increases major histocompatibility complex expression, and promotes T helper 1 lymphocyte

Exhibit Display

Latent tuberculosis infection & active pulmonary tuberculosis disease		
	Latent TB infection	**Active pulmonary TB disease**

Clinical manifestations	Asymptomatic	• Cough
		• Constitutional symptoms
		  ○ Fever/chills, malaise
		  ○ Weight loss, night sweats
		  ○ Anorexia, fatigue

TB transmission	No	Yes
Diagnostic tests	• Positive tuberculin skin test & interferon-γ release assay • Normal chest x-ray • Negative sputum smear/culture	• Positive tuberculin skin test & interferon-γ release assay • Abnormal chest x-ray • Positive sputum smear/culture

TB = tuberculosis.

©UWorld

intracellular bacterial infections. IFN-γ release assays (IGRAs) test for **latent tuberculosis infection** (LTBI) by measuring the response of T lymphocytes when exposed to antigens unique to *Mycobacterium tuberculosis*. Similar to tuberculin skin tests (eg, purified protein derivative), IGRAs measure cell-mediated immunity.

IGRAs have comparable sensitivity and specificity to tuberculin skin tests, but advantages include their lack of cross-reactivity to the Bacille Calmette-Guérin (BCG) vaccine and that a follow-up visit is not required. Neither skin tests nor IGRAs can be used to distinguish active tuberculosis from LTBI.

(Choice A) B lymphocytes are the main cell type involved in the humoral immune system and the production of circulating antibodies.

(Choices B and D) Basophils and antigen-presenting cells such as monocyte-derived macrophages interact with T cells to control the immune response but are not directly responsible for IFN-γ release.

(Choices C and E) Eosinophils help eradicate parasitic infections (eg, helminths), whereas neutrophils are involved in the phagocytosis of bacteria and other pathogens.

Educational objective:
Interferon-gamma (IFN-γ) release assays test for latent tuberculosis infection by measuring the amount of IFN-γ released by T lymphocytes when exposed to antigens unique to *Mycobacterium tuberculosis*.

References

- Gamma interferon release assays for detection of Mycobacterium tuberculosis infection.
- Regulation of interferon-gamma during innate and adaptive immune responses.
- Clinical application and limitations of interferon-gamma release assays for the diagnosis of latent tuberculosis infection.

Microbiology	Allergy & Immunology	Tuberculosis
Subject	System	Topic

Copyright © UWorld. All rights reserved.

A 34-year-old woman comes to the office due to skin changes. Blotches of skin on her arms appear to be of a different color, and she also has a tingling sensation in her hands. These symptoms have developed over the past several months. The patient has no other past medical history. She is a political refugee from East Africa. On examination, there are patchy areas of skin anesthesia and hypopigmentation on her upper extremities. Nerve biopsy evaluated under light microscopy shows many organisms invading Schwann cells. HIV testing is negative. Which of the following organisms is the most likely cause of this patient's condition?

A. *Borrelia burgdorferi*

B. *Campylobacter fetus*

C. *Corynebacterium diphtheriae*

D. *Mycobacterium leprae*

E. *Treponema pallidum*

Submit

A 34-year-old woman comes to the office due to skin changes. Blotches of skin on her arms appear to be of a different color, and she also has a tingling sensation in her hands. These symptoms have developed over the past several months. The patient has no other past medical history. She is a political refugee from East Africa. On examination, there are patchy areas of skin anesthesia and hypopigmentation on her upper extremities. Nerve biopsy evaluated under light microscopy shows many organisms invading Schwann cells. HIV testing is negative. Which of the following organisms is the most likely cause of this patient's condition?

A. *Borrelia burgdorferi* (2%)

B. *Campylobacter fetus* (6%)

C. *Corynebacterium diphtheriae* (1%)

✓ D. *Mycobacterium leprae* (84%)

E. *Treponema pallidum* (4%)

Omitted
Correct answer
D

84%
Answered correctly

02 secs
Time Spent

04/27/2020
Last Updated

Explanation

Immune response in leprosy

Immune response in leprosy

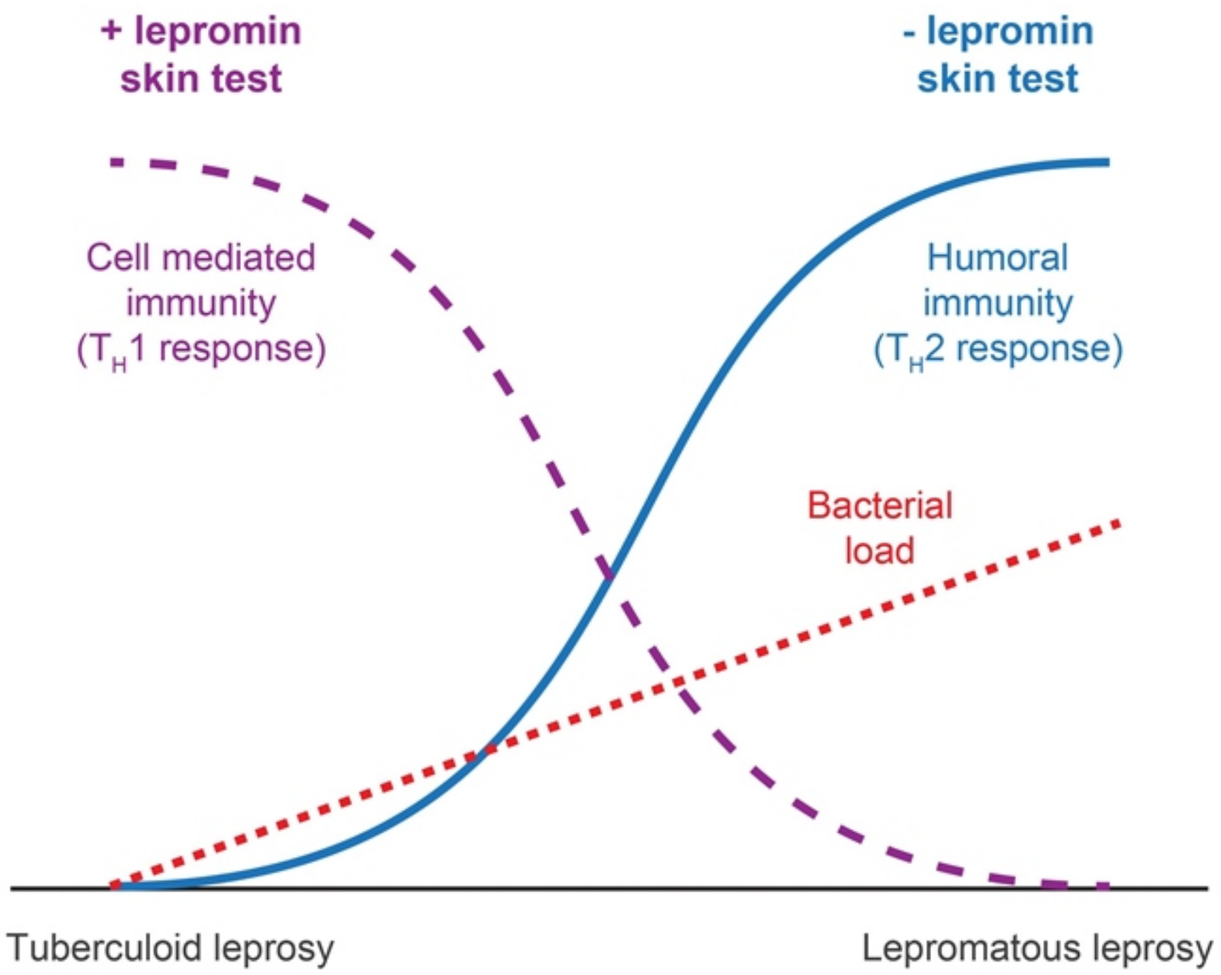

©USMLEWorld, LLC

Leprosy (Hansen disease), a deforming infection primarily of the **skin** and **nerves**, is caused by *Mycobacterium leprae*. Transmission is promoted in unhygienic conditions and likely occurs through the respiratory route, with some organisms being transmitted through prolonged direct skin-to-skin contact. Infection has also been associated with **armadillo** contact in the southwestern United States. The range of clinical manifestations depends on the strength of the **cell-mediated immune** (CMI) response.

- **Tuberculoid leprosy** (TT) (seen in this patient) is the least severe form and is often self-limited. Mycobacterial infection is limited by an **intact CMI** response (**Th1**-mediated). Mild skin plaques develop and are associated with hypopigmentation, hair follicle loss, and focally decreased sensation.
- **Lepromatous leprosy** (LL), the most severe form, occurs in patients with a **weak CMI** response (Th2-mediated). Macrophage signaling to kill *M leprae* is limited, leading to mycobacterial dissemination. Manifestations include diffuse skin thickening, plaque-like hypopigmentation (often with hair loss), leonine facies, paresis, regional anesthesia, testicular destruction, and blindness.

M leprae grows best at temperatures below core body temperature, partially explaining why leprosy manifests in the skin, superficial nerves (eg, Schwann cells in this patient), eyes, and testes. Intermediate features between TT and LL are often seen.

(Choice A) *Borrelia burgdorferi* causes Lyme disease. Symptoms include a characteristic skin rash (erythema chronicum migrans) with fever and malaise. Systemic disease can progress to cause arthritis, facial paresis, or cardiac involvement (eg, conduction abnormalities). Prolonged untreated disease can lead to central nervous system involvement.

(Choice B) *Campylobacter fetus*, a gram-negative rod, causes mild enteritis in immunocompetent patients and mild systemic bacteremic illness in immunocompromised patients.

(Choice C) *Corynebacterium diphtheriae* is a gram-positive rod that causes diphtheria, a primarily toxin-mediated lower respiratory tract infection that is sometimes complicated by polyneuritis and myocarditis.

(Choice E) *Treponema pallidum* causes syphilis. Primary syphilis manifests as a painless chancre at the inoculation site. Secondary syphilis results in erythematous macules over the entire body (including the palms and soles) and condyloma lata formation. Tertiary syphilis results in skin and bone gummas and ascending aortitis.

Educational objective:

- **Lepromatous leprosy** (LL), the most severe form, occurs in patients with a **weak CMI** response (Th2-mediated). Macrophage signaling to kill *M leprae* is limited, leading to mycobacterial dissemination. Manifestations include diffuse skin thickening, plaque-like hypopigmentation (often with hair loss), leonine facies, paresis, regional anesthesia, testicular destruction, and blindness.

M leprae grows best at temperatures below core body temperature, partially explaining why leprosy manifests in the skin, superficial nerves (eg, Schwann cells in this patient), eyes, and testes. Intermediate features between TT and LL are often seen.

(Choice A) *Borrelia burgdorferi* causes Lyme disease. Symptoms include a characteristic skin rash (erythema chronicum migrans) with fever and malaise. Systemic disease can progress to cause arthritis, facial paresis, or cardiac involvement (eg, conduction abnormalities). Prolonged untreated disease can lead to central nervous system involvement.

(Choice B) *Campylobacter fetus*, a gram-negative rod, causes mild enteritis in immunocompetent patients and mild systemic bacteremic illness in immunocompromised patients.

(Choice C) *Corynebacterium diphtheriae* is a gram-positive rod that causes diphtheria, a primarily toxin-mediated lower respiratory tract infection that is sometimes complicated by polyneuritis and myocarditis.

(Choice E) *Treponema pallidum* causes syphilis. Primary syphilis manifests as a painless chancre at the inoculation site. Secondary syphilis results in erythematous macules over the entire body (including the palms and soles) and condyloma lata formation. Tertiary syphilis results in skin and bone gummas and ascending aortitis.

Educational objective:
The severity of leprosy, a systemic illness caused by *Mycobacterium leprae*, depends on the strength of the cell-mediated immune (CMI) response, with tuberculoid leprosy representing the milder form (intact Th1 CMI response) and lepromatous leprosy, the more severe form (weak CMI response).

Microbiology	Dermatology	Leprosy
Subject	System	Topic

Copyright © UWorld. All rights reserved.

A 34-year-old nulligravid woman comes to the office due to vulvar itching and vaginal discharge. She has no other concerns. The patient is sexually active with her fiancé and takes oral contraceptives daily. She does not use barrier contraception. She took antibiotics 2 weeks ago for sinusitis but has no other medical problems. Pelvic examination shows an erythematous vulva and a thick white discharge that adheres to the vaginal wall. The rest of the physical examination is normal. Microscopic examination reveals budding cells. Which of the following is the most likely underlying cause of her current condition?

A. Decreased glycogen concentration in the vaginal epithelium

B. Decreased number of gram-positive bacteria in the vagina

C. Decreased thickness of the vaginal epithelium

D. Increased alkaline secretions by the cervical mucosa

E. Viral DNA incorporation into lower genital epithelia

Submit

A 34-year-old nulligravid woman comes to the office due to vulvar itching and vaginal discharge. She has no other concerns. The patient is sexually active with her fiancé and takes oral contraceptives daily. She does not use barrier contraception. She took antibiotics 2 weeks ago for sinusitis but has no other medical problems. Pelvic examination shows an erythematous vulva and a thick white discharge that adheres to the vaginal wall. The rest of the physical examination is normal. Microscopic examination reveals budding cells. Which of the following is the most likely underlying cause of her current condition?

- A. Decreased glycogen concentration in the vaginal epithelium (6%)
- ✓ B. Decreased number of gram-positive bacteria in the vagina (70%)
- C. Decreased thickness of the vaginal epithelium (2%)
- D. Increased alkaline secretions by the cervical mucosa (19%)
- E. Viral DNA incorporation into lower genital epithelia (1%)

Omitted
Correct answer
B

70%
Answered correctly

01 sec
Time Spent

05/11/2020
Last Updated

Explanation

Differential diagnosis of vaginitis

Diagnosis	Bacterial vaginosis (*Gardnerella vaginalis*)	Trichomoniasis (*Trichomonas vaginalis*)	Candida vaginitis (*Candida albicans*)

Differential diagnosis of vaginitis

Diagnosis	Bacterial vaginosis (*Gardnerella vaginalis*)	Trichomoniasis (*Trichomonas vaginalis*)	Candida vaginitis (*Candida albicans*)
Examination	 • Thin, off-white discharge with fishy odor • No inflammation	 • Thin, yellow-green, malodorous, frothy discharge • Vaginal inflammation	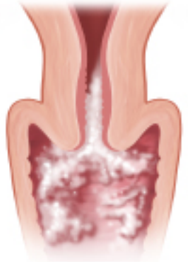 • Thick, "cottage cheese" discharge • Vaginal inflammation
Laboratory findings	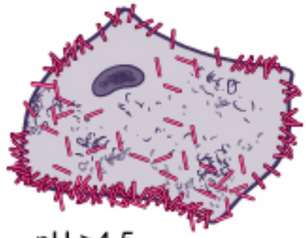 • pH >4.5 • Clue cells • Positive whiff test (amine odor with KOH)	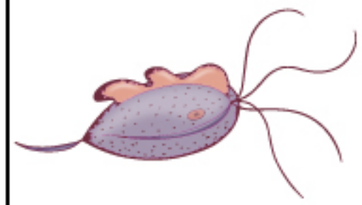 • pH >4.5 • Motile trichomonads	 • Normal pH (3.8-4.5) • Pseudohyphae
Treatment	Metronidazole or clindamycin	Metronidazole; treat sexual partner	Fluconazole

KOH = potassium hydroxide

©UWorld

Gram-positive lactobacilli comprise a major part of the normal vaginal flora and exist in balance with other colonizers at a normal vaginal pH of 3.8-4.5. Changes in vaginal flora and epithelial injury can lead to overgrowth of yeast, most commonly *Candida*. Common triggers for ***Candida* vaginitis** include the following:

- **Antibiotic use**
- **High estrogen** levels (eg, pregnancy)
- Systemic **corticosteroid therapy**
- Uncontrolled **diabetes mellitus**
- Any other cause of **immunosuppression**, including HIV

Antibiotic use is the most common cause of *Candida* vaginitis due to **reduction of the lactobacilli population**, which facilitates *Candida* overgrowth. Patients with *Candida* vaginitis have vulvar/vaginal pruritus and erythema and a thick, white "cottage cheese-like" discharge. Vaginal pH is typically unchanged. Wet mount examination with potassium hydroxide (KOH) preparation is diagnostic and reveals budding yeast and pseudohyphae.

(Choices A and C) Decreased thickness of the vaginal epithelium and decreased amounts of glycogen in epithelial cells are characteristic in postmenopausal and lactating women. These changes are caused by low estrogen levels and lead to atrophic vaginitis.

(Choice D) Elevated pH of vaginal secretions (>4.5) is associated with bacterial vaginosis and *Trichomonas* vaginitis, not *Candida* vaginitis.

(Choice E) Human papillomavirus (HPV) has a predilection for anogenital keratinized skin and mucous membranes. HPV can cause warts, dysplasia, and malignancy by incorporating its DNA into anogenital epithelial cells.

Educational objective:
Antibiotics suppress the normal vaginal flora and facilitate *Candida* overgrowth. Antibiotic use is the most common cause of *Candida* vaginitis. Other potential causes include pregnancy, systemic corticosteroid use, diabetes mellitus, and immunosuppression.

References

- ACOG Practice Bulletin. Clinical management guidelines for obstetrician-gynecologists, Number 72, May 2006: Vaginitis.

- **Antibiotic use**
- **High estrogen** levels (eg, pregnancy)
- Systemic **corticosteroid therapy**
- Uncontrolled **diabetes mellitus**
- Any other cause of **immunosuppression**, including HIV

Antibiotic use is the most common cause of *Candida* vaginitis due to **reduction of the lactobacilli population**, which facilitates *Candida* overgrowth. Patients with *Candida* vaginitis have vulvar/vaginal pruritus and erythema and a thick, white "cottage cheese-like" discharge. Vaginal pH is typically unchanged. Wet mount examination with potassium hydroxide (KOH) preparation is diagnostic and reveals budding yeast and pseudohyphae.

(Choices A and C) Decreased thickness of the vaginal epithelium and decreased amounts of glycogen in epithelial cells are characteristic in postmenopausal and lactating women. These changes are caused by low estrogen levels and lead to atrophic vaginitis.

(Choice D) Elevated pH of vaginal secretions (>4.5) is associated with bacterial vaginosis and *Trichomonas* vaginitis, not *Candida* vaginitis.

(Choice E) Human papillomavirus (HPV) has a predilection for anogenital keratinized skin and mucous membranes. HPV can cause warts, dysplasia, and malignancy by incorporating its DNA into anogenital epithelial cells.

Educational objective:
Antibiotics suppress the normal vaginal flora and facilitate *Candida* overgrowth. Antibiotic use is the most common cause of *Candida* vaginitis. Other potential causes include pregnancy, systemic corticosteroid use, diabetes mellitus, and immunosuppression.

References

- ACOG Practice Bulletin. Clinical management guidelines for obstetrician-gynecologists, Number 72, May 2006: Vaginitis.

Microbiology	Female Reproductive System & Breast	Mucocutaneous candidiasis
Subject	System	Topic

Copyright © UWorld. All rights reserved.

A 55-year-old man comes to the emergency department with fever and chills. He has a history of acute myeloid leukemia for which he is receiving chemotherapy. His temperature is 38.3 C (101 F), blood pressure is 90/50 mm Hg, pulse is 124/min, and respirations are 22/min. Physical examination is notable for multiple skin patches with necrotic centers and occasional ulcerations, as shown in the image below.

Laboratory results are as follows:

Complete blood count	
Platelets	240,000/mm^3
Leukocytes	800/mm^3
Neutrophils	60%
Serum chemistry	
Creatinine	0.9 mg/dL
Coagulation studies	
Prothrombin time	12 sec
Activated partial thromboplastin time	33 sec

Blood cultures are drawn. Which of the following organisms is most likely responsible for this patient's symptoms?

A. *Escherichia coli*

B. *Haemophilus influenzae*

C. *Klebsiella pneumoniae*

A 55-year-old man comes to the emergency department with fever and chills. He has a history of acute myeloid leukemia for which he is receiving chemotherapy. His temperature is 38.3 C (101 F), blood pressure is 90/50 mm Hg, pulse is 124/min, and respirations are 22/min. Physical examination is notable for multiple skin patches with necrotic centers and occasional ulcerations, as shown in the image below.

Displayed with permission from Springer Healthcare Ltd. © Copyright 1997, 2004 by Current Medicine

Laboratory results are as follows:

Complete blood count	
Platelets	240,000/mm^3
Leukocytes	800/mm^3
Neutrophils	60%
Serum chemistry:	

Displayed with permission from Springer Healthcare Ltd. © Copyright 1997, 2004 by Current Medicine

Laboratory results are as follows:

Complete blood count	
Platelets	240,000/mm^3
Leukocytes	800/mm^3
Neutrophils	60%
Serum chemistry	
Creatinine	0.9 mg/dL
Coagulation studies	
Prothrombin time	12 sec
Activated partial thromboplastin time	33 sec

Blood cultures are drawn. Which of the following organisms is most likely responsible for this patient's symptoms?

- A. *Escherichia coli*
- B. *Haemophilus influenzae*
- C. *Klebsiella pneumoniae*
- D. *Pseudomonas aeruginosa*
- E. *Streptococcus pneumoniae*

Leukocytes	800/mm^3
Neutrophils	60%
Serum chemistry	
Creatinine	0.9 mg/dL
Coagulation studies	
Prothrombin time	12 sec
Activated partial thromboplastin time	33 sec

Blood cultures are drawn. Which of the following organisms is most likely responsible for this patient's symptoms?

- A. *Escherichia coli*
- B. *Haemophilus influenzae*
- C. *Klebsiella pneumoniae*
- D. *Pseudomonas aeruginosa*
- E. *Streptococcus pneumoniae*
- F. *Streptococcus pyogenes*

Submit

Leukocytes	800/mm³
Neutrophils	60%
Serum chemistry	
Creatinine	0.9 mg/dL
Coagulation studies	
Prothrombin time	12 sec
Activated partial thromboplastin time	33 sec

Blood cultures are drawn. Which of the following organisms is most likely responsible for this patient's symptoms?

- A. *Escherichia coli* (4%)
- B. *Haemophilus influenzae* (2%)
- C. *Klebsiella pneumoniae* (4%)
- ✓ D. *Pseudomonas aeruginosa* (54%)
- E. *Streptococcus pneumoniae* (3%)
- F. *Streptococcus pyogenes* (30%)

Omitted
Correct answer

54%
Answered correctly

08 secs
Time Spent

03/02/2020
Last Updated

Explanation

This immunosuppressed patient has **febrile neutropenia** (absolute neutrophil count [ANC] of 0.60 × 800 = 480/mm^3, likely in the setting of chemotherapy) and sepsis. With neutropenia (typically ANC <500/mm^3), there is increased susceptibility to infections with gram-negative organisms such as *Pseudomonas aeruginosa*. The dermatologic lesions in this patient are consistent with **ecthyma gangrenosum (EG)**, which is strongly associated with ***P aeruginosa* bacteremia**.

Perivascular bacterial invasion of arteries and veins in the dermis and subcutaneous tissue, with subsequent release of exotoxins destructive to human tissue, leads to characteristic **skin patches** exhibiting **necrosis and ulceration** as a result of insufficient blood flow. *P aeruginosa* virulence factors that may contribute to EG include exotoxin A (protein synthesis inhibition), elastase (degrades elastin - important for blood vessel destruction), phospholipase C (degrades cellular membranes), and pyocyanin (generates reactive oxygen species).

Although gram-negative sepsis is sometimes associated with disseminated intravascular coagulation (DIC) and resultant purpuric skin lesions, DIC is unlikely given the normal platelet count and coagulation times (prothrombin and activated thromboplastin times).

(Choice A) *Escherichia coli* is not associated with EG. *E coli* is the most common cause of gram-negative sepsis, usually following urinary tract infections. Thrombotic thrombocytopenic purpura-hemolytic uremic syndrome, sometimes seen with Shiga toxin-producing *E coli*, is classically associated with renal failure and thrombocytopenia (not seen in this patient).

(Choices B and E) *Streptococcus pneumoniae* and *Haemophilus influenza* are typically associated with respiratory infections and can be isolated from blood, cerebrospinal fluid, or respiratory sources. They are not associated with EG.

(Choice C) *Klebsiella pneumoniae* infection is most commonly associated with necrotizing pneumonia in elderly or immunocompromised patients.

(Choice F) *Streptococcus pyogenes* (Group A *Streptococcus*) frequently causes cutaneous infections (eg, impetigo, erysipelas) and necrotizing fasciitis, a rapidly progressive deep tissue infection that spreads contiguously along the muscle fascia. Necrotizing fasciitis initially appears as a single site of infection with erythema, edema, warmth, and pain out of proportion to physical findings. This progresses to purpuric discoloration, bullae formation, and sensory loss due to tissue necrosis.

Educational objective:
Ecthyma gangrenosum is a cutaneous necrotic disease with a strong association with *Pseudomonas aeruginosa* bacteremia. It occurs from

Although gram-negative sepsis is sometimes associated with disseminated intravascular coagulation (DIC) and resultant purpuric skin lesions, DIC is unlikely given the normal platelet count and coagulation times (prothrombin and activated thromboplastin times).

(Choice A) *Escherichia coli* is not associated with EG. *E coli* is the most common cause of gram-negative sepsis, usually following urinary tract infections. Thrombotic thrombocytopenic purpura-hemolytic uremic syndrome, sometimes seen with Shiga toxin-producing *E coli*, is classically associated with renal failure and thrombocytopenia (not seen in this patient).

(Choices B and E) *Streptococcus pneumoniae* and *Haemophilus influenza* are typically associated with respiratory infections and can be isolated from blood, cerebrospinal fluid, or respiratory sources. They are not associated with EG.

(Choice C) *Klebsiella pneumoniae* infection is most commonly associated with necrotizing pneumonia in elderly or immunocompromised patients.

(Choice F) *Streptococcus pyogenes* (Group A *Streptococcus*) frequently causes cutaneous infections (eg, impetigo, erysipelas) and necrotizing fasciitis, a rapidly progressive deep tissue infection that spreads contiguously along the muscle fascia. Necrotizing fasciitis initially appears as a single site of infection with erythema, edema, warmth, and pain out of proportion to physical findings. This progresses to purpuric discoloration, bullae formation, and sensory loss due to tissue necrosis.

Educational objective:
Ecthyma gangrenosum is a cutaneous necrotic disease with a strong association with *Pseudomonas aeruginosa* bacteremia. It occurs from perivascular invasion and release of tissue-destructive exotoxins, causing vascular destruction and insufficient blood flow to patches of skin that become edematous and subsequently necrose. *Pseudomonas* infections are common in patients who are neutropenic, are hospitalized, have burns, or have indwelling catheters.

References

- Ecthyma gangrenosum: a manifestation of Pseudomonas sepsis in three paediatric patients.

Microbiology	Dermatology	Febrile neutropenia
Subject	System	Topic

Copyright © UWorld. All rights reserved.

Settings

1
2
3
4
5
6
7
8
9
10
11
12
13
14
15
16
17
18
19
20
21
22
23
24
25
26
27
28
29
30

Item 17 of 33
Question Id: 973

Mark | Previous | Next | Full Screen | Tutorial | Lab Values | Notes | Calculator | Reverse Color | Text Zoom | Settings

Although gram-negative sepsis is sometimes associated with disseminated intravascular coagulation (DIC) and resultant purpuric skin lesions,

Exhibit Display

Zoom In | Zoom Out | Reset | Add To New Card | Existing Card

Block Time Remaining: 00:00:56
TUTOR

Feedback | Suspend | End Block

Settings

1 2 3 4 5 6 7 8 9 10 11 12 13 14 15 16 17 18 19 20 21 22 23 24 25 26 27 28 29 30

Item 17 of 33
Question Id: 973

Mark | Previous | Next | Full Screen | Tutorial | Lab Values | Notes | Calculator | Reverse Color | Text Zoom | Settings

Although gram-negative sepsis is sometimes associated with disseminated intravascular coagulation (DIC) and resultant purpuric skin lesions,

Exhibit Display

Zoom In | Zoom Out | Reset | Add To New Card | Existing Card

Block Time Remaining: 00:00:56
TUTOR

Feedback | Suspend | End Block

A 6-month-old boy is brought to the ER with poor feeding and irritability. Physical examination reveals diffuse skin erythema. You also notice that the epidermis easily comes off with gentle pressure. Which of the following is the most likely cause of this patient's symptoms?

A. Microbial skin invasion

B. Endotoxin-mediated inflammatory response

C. Exotoxin-mediated skin damage

D. Mast cell degranulation

E. Cell-mediated hypersensitivity

Submit

A 6-month-old boy is brought to the ER with poor feeding and irritability. Physical examination reveals diffuse skin erythema. You also notice that the epidermis easily comes off with gentle pressure. Which of the following is the most likely cause of this patient's symptoms?

A. Microbial skin invasion (2%)

B. Endotoxin-mediated inflammatory response (12%)

✓ C. Exotoxin-mediated skin damage (70%)

D. Mast cell degranulation (2%)

E. Cell-mediated hypersensitivity (11%)

Omitted
Correct answer
C

70%
Answered correctly

02 secs
Time Spent

02/03/2020
Last Updated

Explanation

Staphylococcal Scalded Skin Syndrome (SSSS) is caused by certain strains of Staphylococcus species that produce the exfoliatin exotoxin. Nikolsky's sign (skin slipping off with gentle pressure), epidermal necrolysis, fever and pain associated with the skin rash are the major symptoms of SSSS. SSSS is most common in infants and young children, and it is frequently not fatal unless the skin lesions become secondarily infected.

Exfoliative toxins show exquisite pathologic specificity in blistering only the superficial epidermis ("epidermolytic"). They act as proteases and cleave desmoglein in desmosomes. Bullous impetigo is a more localized form of SSSS with the bulla formation being another effect of exfoliative toxin.

(Choice A) Examples of microbial skin invasion include impetigo, folliculitis, furuncles, carbuncles, and abscesses. SSSS is caused by a

Staphylococcal Scalded Skin Syndrome (SSSS) is caused by certain strains of Staphylococcus species that produce the exfoliatin exotoxin. Nikolsky's sign (skin slipping off with gentle pressure), epidermal necrolysis, fever and pain associated with the skin rash are the major symptoms of SSSS. SSSS is most common in infants and young children, and it is frequently not fatal unless the skin lesions become secondarily infected.

Exfoliative toxins show exquisite pathologic specificity in blistering only the superficial epidermis ("epidermolytic"). They act as proteases and cleave desmoglein in desmosomes. Bullous impetigo is a more localized form of SSSS with the bulla formation being another effect of exfoliative toxin.

(Choice A) Examples of microbial skin invasion include impetigo, folliculitis, furuncles, carbuncles, and abscesses. SSSS is caused by a circulating exotoxin; the bacterial focus producing the exotoxin can lie anywhere in the body.

(Choice B) Endotoxin-mediated inflammatory response is frequently the cause of septic shock during gram-negative as well as some gram-positive infections (*Listeria*). The lipopolysaccharide fragment "Lipid A" in gram-negative bacteria is a component of the cell membrane and is not actively secreted from the cell as exotoxins are. It is released by bacteriolysis during antibiotic treatment or immune-mediated mechanisms. Exfoliatin is an *EXO*toxin, not an *ENDO*toxin.

(Choice D) Mast cell degranulation is mediated by crosslinking of membrane-bound IgE on the surface of mast cells. This is a component of Type 1 hypersensitivity, or atopy. Conditions caused by this form of hypersensitivity include food allergies, asthma, atopic dermatitis, and allergic rhinitis.

(Choice E) Cell-mediated hypersensitivity, or Type IV delayed-type hypersensitivity, is mediated by sensitized T_H1 cells that secrete cytokines attracting macrophages to a local area. This is the mechanism of many contact dermatitis reactions as well as positivity of the skin tests for tuberculosis exposure (PPD) and for anergy (candida antigen).

Educational Objective:
The staphylococcal scalded skin syndrome occurs in infants and children due to the production of the exotoxin exfoliatin by Staphylococcus species. It causes widespread epidermal sloughing, especially with gentle pressure (Nikolsky's sign).

Microbiology	Dermatology	Staphylococcal scalded skin syndrome
Subject	System	Topic

of SSSS. SSSS is most common in infants and young children, and it is frequently not fatal unless the skin lesions become secondarily infected.

Exfoliative toxins show exquisite pathologic specificity in blistering only the superficial epidermis ("epidermolytic"). They act as proteases and cleave desmoglein in desmosomes. Bullous impetigo is a more localized form of SSSS with the bulla formation being another effect of exfoliative toxin.

(Choice A) Examples of microbial skin invasion include impetigo, folliculitis, furuncles, carbuncles, and abscesses. SSSS is caused by a circulating exotoxin; the bacterial focus producing the exotoxin can lie anywhere in the body.

(Choice B) Endotoxin-mediated inflammatory response is frequently the cause of septic shock during gram-negative as well as some gram-positive infections (*Listeria*). The lipopolysaccharide fragment "Lipid A" in gram-negative bacteria is a component of the cell membrane and is not actively secreted from the cell as exotoxins are. It is released by bacteriolysis during antibiotic treatment or immune-mediated mechanisms. Exfoliatin is an *EXO*toxin, not an *ENDO*toxin.

(Choice D) Mast cell degranulation is mediated by crosslinking of membrane-bound IgE on the surface of mast cells. This is a component of Type 1 hypersensitivity, or atopy. Conditions caused by this form of hypersensitivity include food allergies, asthma, atopic dermatitis, and allergic rhinitis.

(Choice E) Cell-mediated hypersensitivity, or Type IV delayed-type hypersensitivity, is mediated by sensitized T_H1 cells that secrete cytokines attracting macrophages to a local area. This is the mechanism of many contact dermatitis reactions as well as positivity of the skin tests for tuberculosis exposure (PPD) and for anergy (candida antigen).

Educational Objective:
The staphylococcal scalded skin syndrome occurs in infants and children due to the production of the exotoxin exfoliatin by Staphylococcus species. It causes widespread epidermal sloughing, especially with gentle pressure (Nikolsky's sign).

Microbiology	Dermatology	Staphylococcal scalded skin syndrome
Subject	System	Topic

Copyright © UWorld. All rights reserved.

A 46-year-old man comes to the office due to skin lesions that developed on his left arm over the past few days. The lesions are not particularly painful. The patient has never had similar symptoms. He has had no fevers and otherwise feels fine. Past medical history is insignificant. The patient takes no medications and has no allergies. Temperature is 37.1 C (98.8 F). The lesions are shown in the image below.

Displayed with permission from Springer Healthcare Ltd. © Copyright 1995, 2004 by Current Medicine

Following pathologic sampling, the lesions are determined to be fungal in etiology. Which of the following scenarios is most likely a component of this patient's history?

- A. Animal contact
- B. Bat guano exposure
- C. Exposure to seawater

1 2 3 4 5 6 7 8 9 10 11 12 13 14 15 16 17 18 19 20 21 22 23 24 25 26 27 28 29 30

Displayed with permission from Springer Healthcare Ltd. © Copyright 1995, 2004 by Current Medicine

Following pathologic sampling, the lesions are determined to be fungal in etiology. Which of the following scenarios is most likely a component of this patient's history?

- A. Animal contact
- B. Bat guano exposure
- C. Exposure to seawater
- D. Immune system disease
- E. Recent antibiotic use
- F. Thorn prick

Submit

Displayed with permission from Springer Healthcare Ltd. © Copyright 1995, 2004 by Current Medicine

Following pathologic sampling, the lesions are determined to be fungal in etiology. Which of the following scenarios is most likely a component of this patient's history?

- A. Animal contact (5%)
- B. Bat guano exposure (4%)
- C. Exposure to seawater (1%)
- D. Immune system disease (6%)
- E. Recent antibiotic use (1%)
- ✓ F. Thorn prick (80%)

Omitted
Correct answer

80%
Answered correctly

03 secs
Time Spent

05/05/2020
Last Updated

Explanation

This patient has a fungal dermatologic infection. The subcutaneous nodules pictured are consistent with **sporotrichosis**, a subcutaneous mycosis caused by *Sporothrix schenckii*. *Sporothrix* is a dimorphic **fungus** found in the natural environment in the form of mold (hyphae). It resides on the bark of trees, shrubs, and garden plants and on plant debris in soil. It enters the body through breaks in the skin (often via **thorn prick**) and spreads along the **lymphatics**. Sporotrichosis is commonly seen in gardeners.

The initial lesion - a reddish nodule that later ulcerates - appears at the site of the thorn prick or other skin injury. Biopsy of the lesion typically reveals a **granuloma** consisting of histiocytes, multinucleated giant cells, and neutrophils, surrounded by plasma cells. From the site of inoculation, the fungus spreads along the lymphatics, forming subcutaneous nodules and ulcers.

The diagnosis of sporotrichosis is made by culturing the affected area and isolating *S schenckii*. Antifungal therapy (eg, itraconazole) is needed.

(Choice A) Animal contact is associated with dermatophytoses caused by *Microsporum* species. *Microsporum canis* causes tinea capitis. Cat scratch disease (manifesting as a vesicle turning into a papule and accompanied by lymphadenopathy) is due to *Bartonella*, which is a gram-negative bacterium, not a fungus.

(Choice B) Exposure to bats (eg, during cave exploration) or to bird droppings in the Ohio and Mississippi River Valley areas is associated with *Histoplasma capsulatum* infection, which typically causes lung disease resembling tuberculosis.

(Choice C) The bacterial organisms *Aeromonas* and *Vibrio vulnificus* may cause cellulitis related to freshwater or seawater exposure.

(Choice D) Immune system disease predisposes to systemic mycoses (eg, candidiasis, aspergillosis, mucormycosis). Sporotrichosis, in contrast, commonly affects immunocompetent individuals. Disseminated sporotrichosis is very rare.

(Choice E) Recent antibiotic use is associated with superficial *Candida* disease, such as oral thrush or vulvovaginitis.

Educational objective:
Sporothrix schenckii is a dimorphic fungus that causes a subcutaneous mycosis. It is often transmitted by a thorn prick. The disease manifests with nodules that spread along lymphatics.

Microbiology Dermatology Sporotrichosis

resides on the bark of trees, shrubs, and garden plants and on plant debris in soil. It enters the body through breaks in the skin (often via **thorn prick**) and spreads along the **lymphatics**. Sporotrichosis is commonly seen in gardeners.

The initial lesion - a reddish nodule that later ulcerates - appears at the site of the thorn prick or other skin injury. Biopsy of the lesion typically reveals a **granuloma** consisting of histiocytes, multinucleated giant cells, and neutrophils, surrounded by plasma cells. From the site of inoculation, the fungus spreads along the lymphatics, forming subcutaneous nodules and ulcers.

The diagnosis of sporotrichosis is made by culturing the affected area and isolating *S schenckii*. Antifungal therapy (eg, itraconazole) is needed.

(Choice A) Animal contact is associated with dermatophytoses caused by *Microsporum* species. *Microsporum canis* causes tinea capitis. Cat scratch disease (manifesting as a vesicle turning into a papule and accompanied by lymphadenopathy) is due to *Bartonella*, which is a gram-negative bacterium, not a fungus.

(Choice B) Exposure to bats (eg, during cave exploration) or to bird droppings in the Ohio and Mississippi River Valley areas is associated with *Histoplasma capsulatum* infection, which typically causes lung disease resembling tuberculosis.

(Choice C) The bacterial organisms *Aeromonas* and *Vibrio vulnificus* may cause cellulitis related to freshwater or seawater exposure.

(Choice D) Immune system disease predisposes to systemic mycoses (eg, candidiasis, aspergillosis, mucormycosis). Sporotrichosis, in contrast, commonly affects immunocompetent individuals. Disseminated sporotrichosis is very rare.

(Choice E) Recent antibiotic use is associated with superficial *Candida* disease, such as oral thrush or vulvovaginitis.

Educational objective:
Sporothrix schenckii is a dimorphic fungus that causes a subcutaneous mycosis. It is often transmitted by a thorn prick. The disease manifests with nodules that spread along lymphatics.

Microbiology	Dermatology	Sporotrichosis
Subject	System	Topic

Copyright © UWorld. All rights reserved.

An 8-year-old Middle Eastern immigrant is brought to the physician by his parents for a low-grade fever and skin rash. The child's mother says that the rash started on his face and spread rapidly down his body. The boy recently returned from a month-long trip to Yemen, where he visited relatives. Physical examination shows a generalized, fine, pinkish maculopapular rash and tender lymphadenopathy bilaterally behind the ears. Which of the following is the most likely cause of this patient's disease?

- A. Herpesvirus
- B. Togavirus
- C. Reovirus
- D. Paramyxovirus
- E. Parvovirus

Submit

An 8-year-old Middle Eastern immigrant is brought to the physician by his parents for a low-grade fever and skin rash. The child's mother says that the rash started on his face and spread rapidly down his body. The boy recently returned from a month-long trip to Yemen, where he visited relatives. Physical examination shows a generalized, fine, pinkish maculopapular rash and tender lymphadenopathy bilaterally behind the ears. Which of the following is the most likely cause of this patient's disease?

- A. Herpesvirus (3%)
- ✓ B. Togavirus (51%)
- C. Reovirus (2%)
- D. Paramyxovirus (31%)
- E. Parvovirus (10%)

Omitted
Correct answer
B

51%
Answered correctly

02 secs
Time Spent

05/25/2020
Last Updated

Explanation

Many immigrants to the United States will not have completed the vaccination regimen recommended by the Centers for Disease Control and Prevention. It is likely that this patient was not vaccinated against measles, mumps, and rubella (MMR) at age 12-15 months. Among the acute viral exanthems, measles (rubeola) and German measles (rubella) are characterized by a maculopapular rash that begins on the face and spreads to the trunk and extremities. Compared to rubeola, the rash of rubella typically spreads faster and does not darken or coalesce. Postauricular and occipital lymphadenopathy is particularly common in rubella, which is caused by a togavirus.

Many immigrants to the United States will not have completed the vaccination regimen recommended by the Centers for Disease Control and Prevention. It is likely that this patient was not vaccinated against measles, mumps, and rubella (MMR) at age 12-15 months. Among the acute viral exanthems, measles (rubeola) and German measles (rubella) are characterized by a maculopapular rash that begins on the face and spreads to the trunk and extremities. Compared to rubeola, the rash of rubella typically spreads faster and does not darken or coalesce. Postauricular and occipital lymphadenopathy is particularly common in rubella, which is caused by a togavirus.

(Choice A) Varicella zoster virus tends to produce a maculopapular rash that begins on the trunk and spreads centrifugally to involve the face and extremities. Roseola (HHV-6) causes exanthem subitum (also called roseola infantum), which is characterized by a transient maculopapular rash that appears for a few days on the chest and trunk once the patient's fever subsides.

(Choice C) A coltivirus in the Reoviridae family is responsible for Colorado tick fever. This infection occurs primarily in the Rocky Mountain states and is characterized by fever, vomiting, myalgias, and weakness. A maculopapular rash is not typically seen.

(Choice D) Among the paramyxoviruses of medical importance, only measles (rubeola) typically produces a rash. Rubella is more often associated with postauricular lymphadenopathy and tenderness than is rubeola.

(Choice E) A parvovirus is responsible for fifth disease (erythema infectiosum). This illness is first characterized by redness of the cheeks ("slapped-cheek" appearance), followed by a maculopapular rash on the extremities and trunk. Postauricular tenderness is not a common manifestation.

Educational objective:
In a susceptible child, a febrile maculopapular rash that begins on the face and spreads to the trunk and extremities is suggestive of rubeola (measles) or rubella (German measles). The additional finding of postauricular lymphadenopathy indicates that rubella is the most likely etiology.

Microbiology	Dermatology	Rubella
Subject	System	Topic

Copyright © UWorld. All rights reserved.

Settings

1
2
3
4
5
6
7
8
9
10
11
12
13
14
15
16
17
18
19
20
21
22
23
24
25
26
27
28
29
30

Item 20 of 33
Question Id: 1669

Mark | Previous | Next | Full Screen | Tutorial | Lab Values | Notes | Calculator | Reverse Color | Text Zoom | Settings

Exhibit Display

Zoom In | Zoom Out | Reset | Add To New Card | Existing Card

Block Time Remaining: 00:01:03
TUTOR

4 | Feedback | Suspend | End Block

Settings

1
2
3
4
5
6
7
8
9
10
11
12
13
14
15
16
17
18
19
20
21
22
23
24
25
26
27
28
29
30

Item 20 of 33
Question Id: 1669

Mark | Previous | Next | Full Screen | Tutorial | Lab Values | Notes | Calculator | Reverse Color | Text Zoom | Settings

Exhibit Display

Zoom In | Zoom Out | Reset | Add To New Card | Existing Card

Block Time Remaining: 00:01:03
TUTOR

4 | Feedback | Suspend | End Block

A 22-year-old man comes to the office due to skin lesions. The patient noticed a nonpainful, nonpruritic skin bump on his right knee 3 months ago, which progressively increased in size and number. He has no prior health issues and takes no medications. The patient is outdoors frequently for work and recreational activities. He is sexually active. Physical examination findings are shown in the exhibit. Which of the following microbial organisms is most likely responsible for this patient's current condition?

A. Coxsackievirus

B. Herpes simplex virus

C. Human papillomavirus

D. *Neisseria gonorrhoeae*

E. Pox virus

F. *Treponema pallidum*

Submit

A 22-year-old man comes to the office due to skin lesions. The patient noticed a nonpainful, nonpruritic skin bump on his right knee 3 months ago, which progressively increased in size and number. He has no prior health issues and takes no medications. The patient is outdoors frequently for work and recreational activities. He is sexually active. Physical examination findings are shown in the exhibit. Which of the following microbial organisms is most likely responsible for this patient's current condition?

- A. Coxsackievirus (1%)
- B. Herpes simplex virus (3%)
- ✓ C. Human papillomavirus (53%)
- D. *Neisseria gonorrhoeae* (2%)
- E. Pox virus (35%)
- F. *Treponema pallidum* (3%)

Omitted
Correct answer
C

53%
Answered correctly

02 secs
Time Spent

05/07/2020
Last Updated

Explanation

Cutaneous warts (verruca vulgaris)	
Etiology	• Human papillomavirus • Acquired by direct contact

Cutaneous warts (verruca vulgaris)	
Etiology	• Human papillomavirus • Acquired by direct contact
Appearance	• Plaques, papules, verrucous lesions • Skin, nail folds, palms/soles • Thrombosed capillaries on magnified view
Histopathology	• Thickening of stratum corneum • Epidermal hyperplasia & papilloma formation • Cytoplasmic vacuolization (koilocytosis)
Natural history	• Gradual, chronic course • Spontaneous resolution (usually <2 years) • Possible recurrence

This patient has **cutaneous warts** (verruca vulgaris), presenting as painless, **skin-colored papules** with a dry, whitish surface. Warts may be single or multiple and can also form irregular plaques or complex filiform structures. The diagnosis of cutaneous warts is usually made on inspection, although a magnified view (ie, dermatoscopy) can be helpful and typically reveals small black dots representing thrombosed capillaries.

Cutaneous warts are caused by **human papillomavirus** (HPV), which is also the cause of plantar warts and anogenital warts (ie, condyloma acuminata). Infection is most prevalent in children, adolescents, and young adults and is usually acquired through **direct contact**. Immunosuppressed patients (eg, HIV infection) are at increased risk and often develop numerous, large lesions.

Although the HPV family is associated with an increased risk for mucosal squamous cell carcinoma (eg, cervical cancer), this is primarily related to high-risk HPV types (eg, 16, 18); most cutaneous warts are due to low-risk types (eg, 2, 4), and malignant transformation is rare.

(Choice A) Coxsackievirus is the most common etiologic agent in hand-foot-and-mouth disease, which is characterized by low-grade fever and vesicles/ulcers on the oral mucosa and skin (especially hands and feet). Chronic papules are more consistent with cutaneous warts.

This patient has **cutaneous warts** (verruca vulgaris), presenting as painless, **skin-colored papules** with a dry, whitish surface. Warts may be single or multiple and can also form irregular plaques or complex filiform structures. The diagnosis of cutaneous warts is usually made on inspection, although a magnified view (ie, dermatoscopy) can be helpful and typically reveals small black dots representing thrombosed capillaries.

Cutaneous warts are caused by **human papillomavirus** (HPV), which is also the cause of plantar warts and anogenital warts (ie, condyloma acuminata). Infection is most prevalent in children, adolescents, and young adults and is usually acquired through **direct contact**. Immunosuppressed patients (eg, HIV infection) are at increased risk and often develop numerous, large lesions.

Although the HPV family is associated with an increased risk for mucosal squamous cell carcinoma (eg, cervical cancer), this is primarily related to high-risk HPV types (eg, 16, 18); most cutaneous warts are due to low-risk types (eg, 2, 4), and malignant transformation is rare.

(Choice A) Coxsackievirus is the most common etiologic agent in hand-foot-and-mouth disease, which is characterized by low-grade fever and vesicles/ulcers on the oral mucosa and skin (especially hands and feet). Chronic papules are more consistent with cutaneous warts.

(Choice B) Herpes simplex virus causes herpetic whitlow, which presents acutely with a prodrome of burning/tingling followed by single or multiple vesicles on an erythematous base.

(Choice D) Disseminated gonococcal infection causes a pustular or bullous rash, which commonly involves both the extremities and torso. It is typically associated with tenosynovitis and migratory polyarthralgia.

(Choice E) Molluscum contagiosum is caused by a pox virus. Although it commonly presents as small papules, the lesions are smooth, pearly, and umbilicated, unlike the rough, dry lesions in this patient.

(Choice F) Condyloma lata is a manifestation of secondary syphilis, caused by *Treponema pallidum*. Although it may present as verruciform lesions, it is often associated with fever and lymphadenopathy and is most common on the oral mucosa or genital area near the site of primary infection.

Educational objective:
Cutaneous warts are caused by human papillomavirus (HPV) and typically present as skin-colored papules with a dry, whitish surface. HPV is usually transmitted by direct contact.

References

Settings

1
2
3
4
5
6
7
8
9
10
11
12
13
14
15
16
17
18
19
20
21
22
23
24
25
26
27
28
29
30

Item 21 of 33
Question Id: 15364

Mark | Previous | Next | Full Screen | Tutorial | Lab Values | Notes | Calculator | Reverse Color | Text Zoom | Settings

This patient has **cutaneous warts** (verruca vulgaris), presenting as painless, **skin-colored papules** with a dry, whitish surface. Warts may be

Exhibit Display

Zoom In | Zoom Out | Reset | Add To Flash Card

References

Block Time Remaining: 00:01:05
TUTOR

0 | Feedback | Suspend | End Block

Settings

1 2 3 4 5 6 7 8 9 10 11 12 13 14 15 16 17 18 19 20 21 22 23 24 25 26 27 28 29 30

Item 21 of 33
Question Id: 15364

Mark | Previous | Next | Full Screen | Tutorial | Lab Values | Notes | Calculator | Reverse Color | Text Zoom | Settings

This patient has **cutaneous warts** (verruca vulgaris), presenting as painless, **skin-colored papules** with a dry, whitish surface. Warts may be

Exhibit Display

Zoom In | Zoom Out | Reset | Add To Flash Card

References

Block Time Remaining: 00:01:05
TUTOR

0 | Feedback | Suspend | End Block

Settings

1 2 3 4 5 6 7 8 9 10 11 12 13 14 15 16 17 18 19 20 21 22 23 24 25 26 27 28 29 30

Item 21 of 33
Question Id: 15364

Mark | Previous | Next | Full Screen | Tutorial | Lab Values | Notes | Calculator | Reverse Color | Text Zoom | Settings

This patient has **cutaneous warts** (verruca vulgaris), presenting as painless, **skin-colored papules** with a dry, whitish surface. Warts may be

Exhibit Display

Zoom In | Zoom Out | Reset | Add To Flash Card

References

Block Time Remaining: 00:01:05
TUTOR

0 | Feedback | Suspend | End Block

Settings

1 2 3 4 5 6 7 8 9 10 11 12 13 14 15 16 17 18 19 20 21 22 23 24 25 26 27 28 29 30

Item 21 of 33
Question Id: 15364

Mark | Previous | Next | Full Screen | Tutorial | Lab Values | Notes | Calculator | Reverse Color | Text Zoom | Settings

This patient has **cutaneous warts** (verruca vulgaris), presenting as painless, **skin-colored papules** with a dry, whitish surface. Warts may be

Exhibit Display

Zoom In | Zoom Out | Reset | Add To Flash Card

References

Block Time Remaining: 00:01:05
TUTOR

0 | Feedback | Suspend | End Block

Settings

1 2 3 4 5 6 7 8 9 10 11 12 13 14 15 16 17 18 19 20 21 22 23 24 25 26 27 28 29 30

Item 21 of 33
Question Id: 15364

Mark | Previous | Next | Full Screen | Tutorial | Lab Values | Notes | Calculator | Reverse Color | Text Zoom | Settings

This patient has **cutaneous warts** (verruca vulgaris), presenting as painless, **skin-colored papules** with a dry, whitish surface. Warts may be

Exhibit Display

Zoom In | Zoom Out | Reset | Add To Flash Card

References

Block Time Remaining: 00:01:05
TUTOR

0 | Feedback | Suspend | End Block

Settings

1 2 3 4 5 6 7 8 9 10 11 12 13 14 15 16 17 18 19 20 21 22 23 24 25 26 27 28 29 30

Item 21 of 33
Question Id: 15364

Mark | Previous | Next | Full Screen | Tutorial | Lab Values | Notes | Calculator | Reverse Color | Text Zoom | Settings

This patient has **cutaneous warts** (verruca vulgaris), presenting as painless, **skin-colored papules** with a dry, whitish surface. Warts may be

Exhibit Display

Zoom In | Zoom Out | Reset | Add To Flash Card

References

Block Time Remaining: 00:01:05
TUTOR

0 | Feedback | Suspend | End Block

Settings

1
2
3
4
5
6
7
8
9
10
11
12
13
14
15
16
17
18
19
20
21
22
23
24
25
26
27
28
29
30

Item 21 of 33
Question Id: 15364

Mark | Previous | Next | Full Screen | Tutorial | Lab Values | Notes | Calculator | Reverse Color | Text Zoom | Settings

Although the HPV family is associated with an increased risk for mucosal squamous cell carcinoma (eg, cervical cancer), this is primarily related to

Exhibit Display

Zoom In | Zoom Out | Reset | Add To Flash Card

Block Time Remaining: 00:01:05
TUTOR

0 | Feedback | Suspend | End Block

Settings

1
2
3
4
5
6
7
8
9
10
11
12
13
14
15
16
17
18
19
20
21
22
23
24
25
26
27
28
29
30

Item 21 of 33
Question Id: 15364

Mark | Previous | Next | Full Screen | Tutorial | Lab Values | Notes | Calculator | Reverse Color | Text Zoom | Settings

Although the HPV family is associated with an increased risk for mucosal squamous cell carcinoma (eg, cervical cancer), this is primarily related to

Exhibit Display

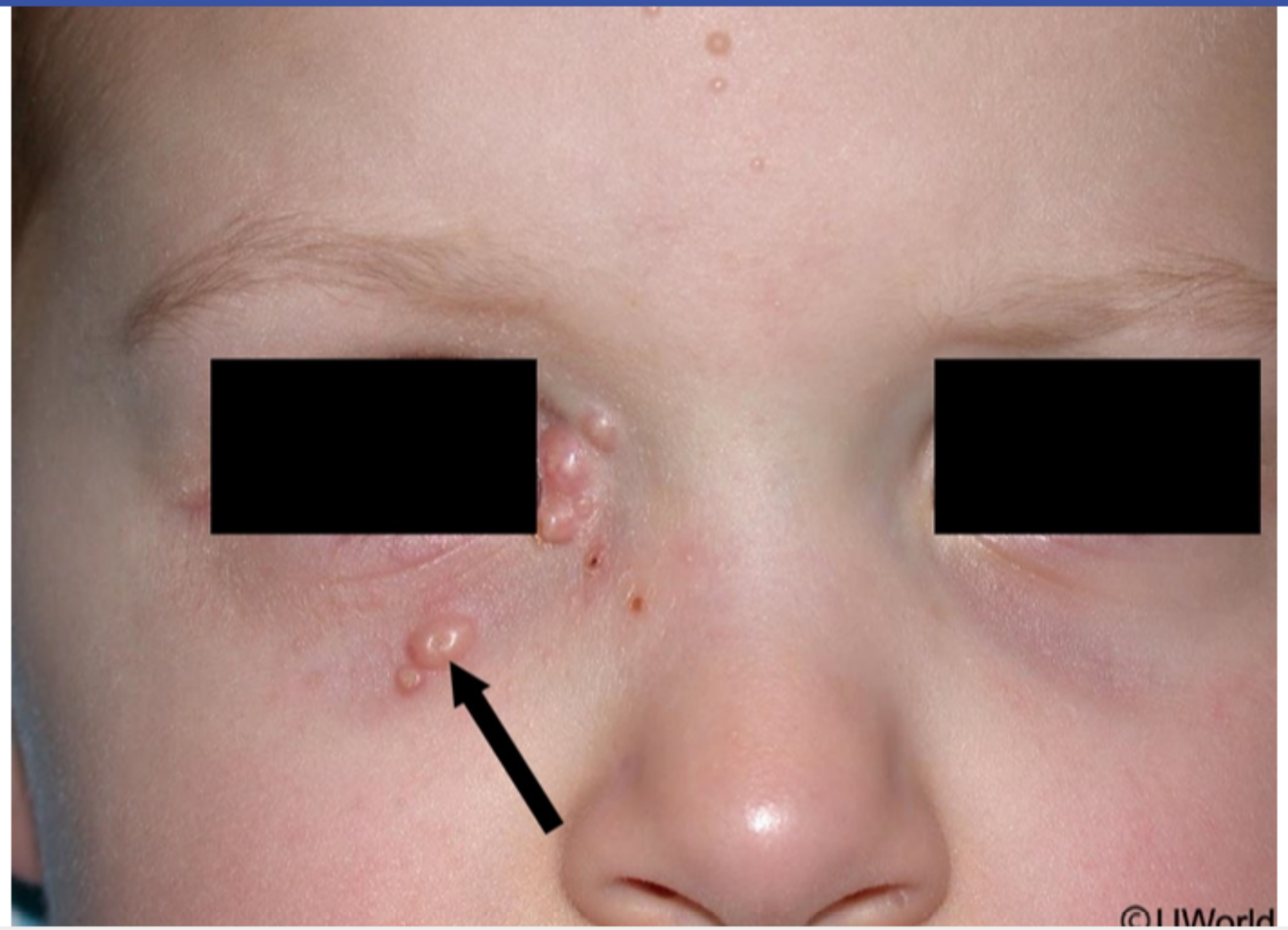

Zoom In | Zoom Out | Reset | Add To Flash Card

Block Time Remaining: 00:01:05
TUTOR

0 | Feedback | Suspend | End Block

A 62-year-old man is brought to the emergency department from a homeless shelter due to alcohol intoxication. The patient has no other symptoms or history of significant medical conditions. Examination of the scalp reveals the findings shown in the exhibit. Which of the following organisms is most likely responsible for this patient's condition?

A. *Cimex lectularius*

B. *Malassezia* species

C. *Pediculus humanus capitis*

D. *Pthirus pubis*

E. *Sarcoptes scabei*

F. *Trichophyton tonsurans*

Submit

A 62-year-old man is brought to the emergency department from a homeless shelter due to alcohol intoxication. The patient has no other symptoms or history of significant medical conditions. Examination of the scalp reveals the findings shown in the exhibit. Which of the following organisms is most likely responsible for this patient's condition?

- A. *Cimex lectularius* (1%)
- B. *Malassezia* species (5%)
- ✓ C. *Pediculus humanus capitis* (73%)
- D. *Pthirus pubis* (5%)
- E. *Sarcoptes scabei* (8%)
- F. *Trichophyton tonsurans* (5%)

Omitted
Correct answer
C

73%
Answered correctly

02 secs
Time Spent

04/15/2020
Last Updated

Explanation

This patient has numerous **nits**, which are egg casings of the head louse *Pediculus humanus capitis*. **Pediculosis capitis** (ie, head lice infestation) is common in school children and adults who come into close contact with infested individuals (eg, sports teams, homeless shelters). Transmission is usually by **direct contact**, although transmission by fomites (eg, hats, hairbrushes) can also occur. Head lice require multiple blood meals a day and die within 2 days if separated from a host. They do not carry arthropod-borne infection, but the bite can induce a pruritic allergic reaction.

This patient has numerous **nits**, which are egg casings of the head louse *Pediculus humanus capitis*. **Pediculosis capitis** (ie, head lice infestation) is common in school children and adults who come into close contact with infested individuals (eg, sports teams, homeless shelters). Transmission is usually by **direct contact**, although transmission by fomites (eg, hats, hairbrushes) can also occur. Head lice require multiple blood meals a day and die within 2 days if separated from a host. They do not carry arthropod-borne infection, but the bite can induce a pruritic allergic reaction.

Female lice attach their nits to the hair shaft about 0.5 cm from the skin surface; nits further from the surface often represent old egg casings that have hatched and generally do not require treatment. First-line treatment includes **topical pediculicides** (eg, permethrin, ivermectin). Manual lice removal via **wet combing** is an alternate treatment for patients for whom standard pediculicides are not feasible (eg, children age <2 years, resource-poor populations).

(Choice A) *Cimex lectularius* (ie, bedbugs) bites present as pruritic, red papules in clusters. The females lay eggs away from the host and do not produce nits.

(Choice B) Colonization with *Malassezia* yeasts is associated with seborrheic dermatitis. On the scalp, this condition can produce white skin flakes in the hair (ie, dandruff). The flakes are not adherent to the hair shaft and are typically found loosely throughout the hair and on the clothing.

(Choice D) *Pthirus pubis* (ie, crab louse, pubic louse) is usually transmitted by sexual contact. The louse is adapted for attaching to thick hair shafts, and the nits are usually found on pubic and other thick hair (eg, eyelashes); however, scalp hair is not typically affected.

(Choice E) *Sarcoptes scabei* causes scabies, which presents with pruritic papules and burrows on the interdigital and flexural skin of the extremities. The female mite lays eggs in burrows and does not form nits.

(Choice F) *Trichophyton tonsurans* is a dermatophyte that causes tinea capitis, which presents as a scaly, erythematous patch of hair loss. There are often small, black dots that represent broken hair shafts.

Educational objective:
Pediculus humanus capitis (ie, head lice) infestation is common in school children and adults who come into close contact with infested individuals. Transmission is usually by direct contact. The eggs (nits) are attached to the hair shaft and can be identified on inspection. Head lice do not carry infection, but the bite can induce a pruritic allergic reaction. First-line treatment includes topical pediculicides (eg, permethrin,

Female lice attach their nits to the hair shaft about 0.5 cm from the skin surface; nits further from the surface often represent old egg casings that have hatched and generally do not require treatment. First-line treatment includes **topical pediculicides** (eg, permethrin, ivermectin). Manual lice removal via **wet combing** is an alternate treatment for patients for whom standard pediculicides are not feasible (eg, children age <2 years, resource-poor populations).

(Choice A) *Cimex lectularius* (ie, bedbugs) bites present as pruritic, red papules in clusters. The females lay eggs away from the host and do not produce nits.

(Choice B) Colonization with *Malassezia* yeasts is associated with seborrheic dermatitis. On the scalp, this condition can produce white skin flakes in the hair (ie, dandruff). The flakes are not adherent to the hair shaft and are typically found loosely throughout the hair and on the clothing.

(Choice D) *Pthirus pubis* (ie, crab louse, pubic louse) is usually transmitted by sexual contact. The louse is adapted for attaching to thick hair shafts, and the nits are usually found on pubic and other thick hair (eg, eyelashes); however, scalp hair is not typically affected.

(Choice E) *Sarcoptes scabei* causes scabies, which presents with pruritic papules and burrows on the interdigital and flexural skin of the extremities. The female mite lays eggs in burrows and does not form nits.

(Choice F) *Trichophyton tonsurans* is a dermatophyte that causes tinea capitis, which presents as a scaly, erythematous patch of hair loss. There are often small, black dots that represent broken hair shafts.

Educational objective:
Pediculus humanus capitis (ie, head lice) infestation is common in school children and adults who come into close contact with infested individuals. Transmission is usually by direct contact. The eggs (nits) are attached to the hair shaft and can be identified on inspection. Head lice do not carry infection, but the bite can induce a pruritic allergic reaction. First-line treatment includes topical pediculicides (eg, permethrin, ivermectin).

Microbiology	Dermatology	Lice infestation
Subject	System	Topic

Copyright © UWorld. All rights reserved.

Settings

1
2
3
4
5
6
7
8
9
10
11
12
13
14
15
16
17
18
19
20
21
22
23
24
25
26
27
28
29
30

Item 22 of 33
Question Id: 17230

Mark | Previous | Next | Full Screen | Tutorial | Lab Values | Notes | Calculator | Reverse Color | Text Zoom | Settings

Exhibit Display

Zoom In | Zoom Out | Reset | Add To New Card | Existing Card

(Choice B) Colonization with *Malassezia* yeasts is associated with seborrheic dermatitis. On the scalp, this condition can produce white skin

Block Time Remaining: 00:01:07
TUTOR

4 | Feedback | Suspend | End Block

Settings

1 2 3 4 5 6 7 8 9 10 11 12 13 14 15 16 17 18 19 20 21 22 23 24 25 26 27 28 29 30

Item 22 of 33
Question Id: 17230

Mark | Previous | Next | Full Screen | Tutorial | Lab Values | Notes | Calculator | Reverse Color | Text Zoom | Settings

Exhibit Display

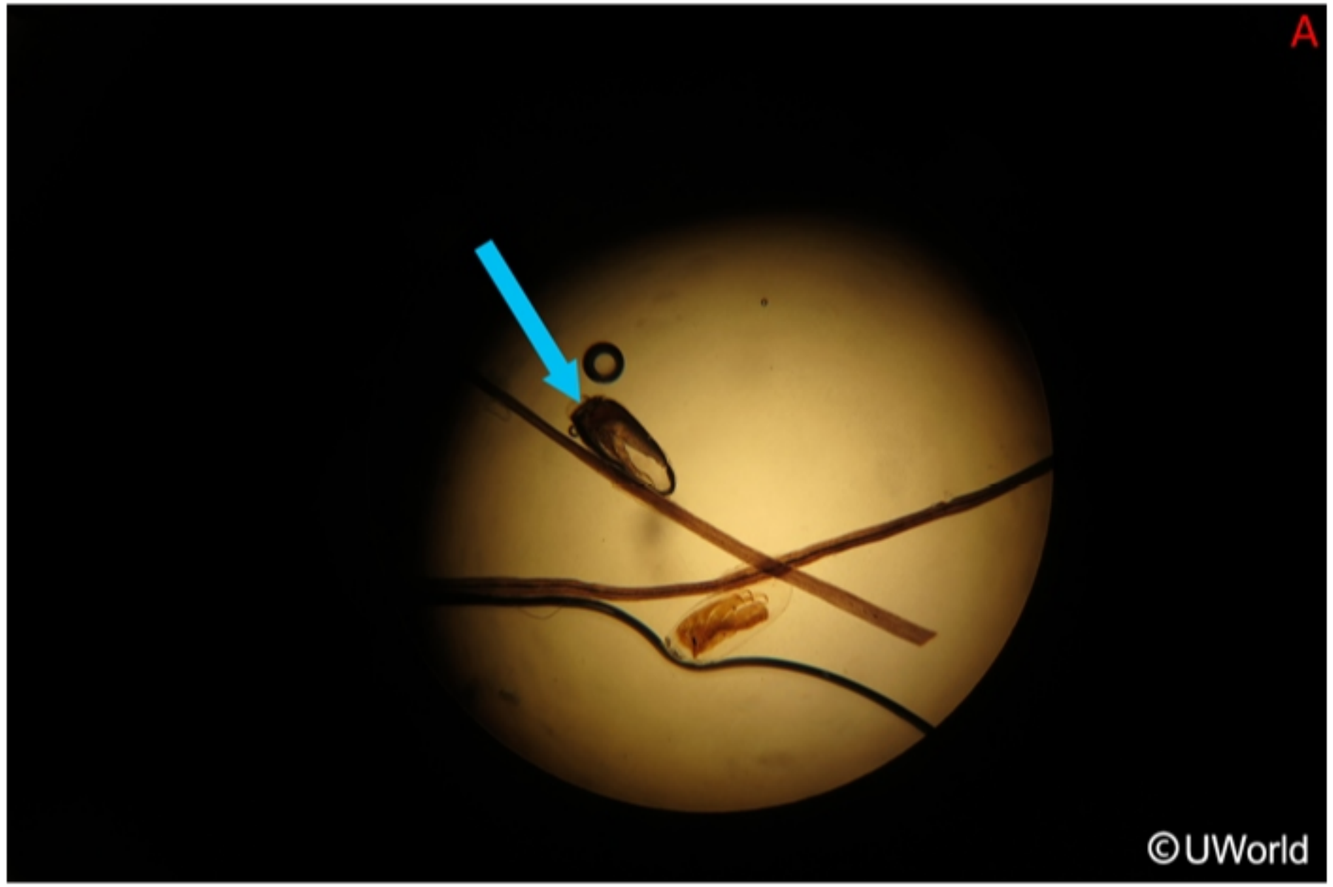

Zoom In | Zoom Out | Reset | Add To New Card | Existing Card

(Choice B) Colonization with *Malassezia* yeasts is associated with seborrheic dermatitis. On the scalp, this condition can produce white skin

Block Time Remaining: 00:01:07
TUTOR

4 | Feedback | Suspend | End Block

Female lice attach their nits to the hair shaft about 0.5 cm from the skin surface; nits further from the surface often represent old egg casings that have hatched and generally do not require treatment. First-line treatment includes **topical pediculicides** (eg, permethrin, ivermectin). Manual lice removal via **wet combing** is an alternate treatment for patients for whom standard pediculicides are not feasible (eg, children age <2 years, resource-poor populations).

(Choice A) *Cimex lectularius* (ie, bedbugs) bites present as pruritic, red papules in clusters. The females lay eggs away from the host and do not produce nits.

(Choice B) Colonization with *Malassezia* yeasts is associated with seborrheic dermatitis. On the scalp, this condition can produce white skin flakes in the hair (ie, dandruff). The flakes are not adherent to the hair shaft and are typically found loosely throughout the hair and on the clothing.

(Choice D) *Pthirus pubis* (ie, crab louse, pubic louse) is usually transmitted by sexual contact. The louse is adapted for attaching to thick hair shafts, and the nits are usually found on pubic and other thick hair (eg, eyelashes); however, scalp hair is not typically affected.

(Choice E) *Sarcoptes scabei* causes scabies, which presents with pruritic papules and burrows on the interdigital and flexural skin of the extremities. The female mite lays eggs in burrows and does not form nits.

(Choice F) *Trichophyton tonsurans* is a dermatophyte that causes tinea capitis, which presents as a scaly, erythematous patch of hair loss. There are often small, black dots that represent broken hair shafts.

Educational objective:
Pediculus humanus capitis (ie, head lice) infestation is common in school children and adults who come into close contact with infested individuals. Transmission is usually by direct contact. The eggs (nits) are attached to the hair shaft and can be identified on inspection. Head lice do not carry infection, but the bite can induce a pruritic allergic reaction. First-line treatment includes topical pediculicides (eg, permethrin, ivermectin).

Microbiology	Dermatology	Lice infestation
Subject	System	Topic

Copyright © UWorld. All rights reserved.

follows:

Complete blood count	
Hemoglobin	12 g/dL
Mean corpuscular volume	82 fL
Platelets	200,000/mm^3
Leukocytes	9,000/mm^3
Urine β-hCG	Positive

Prior infection with which of the following microorganisms is most likely responsible for this patient's current condition?

- A. *Escherichia coli*
- B. *Gardnerella vaginalis*
- C. Herpes simplex virus
- D. Molluscum contagiosum virus
- E. *Neisseria gonorrhoeae*
- F. *Treponema pallidum*
- G. *Trichomonas vaginalis*

Submit

A 23-year-old woman comes to the office for evaluation of right lower abdominal pain and bloody vaginal discharge. The symptoms began this morning and are worsening. She is sexually active with one male partner. They use condoms occasionally, but the patient is not sure whether her partner has other sexual partners. She was treated for an infection "in her private area" a few years ago but cannot recall the condition. The patient currently takes no medications and has no allergies. Her last menstrual period was 5 weeks ago, and she has never been pregnant. Blood pressure is 112/70 mm Hg while supine and 96/60 mm Hg while standing. She is tachycardic and ill-appearing. Laboratory results are as follows:

Complete blood count	
Hemoglobin	12 g/dL
Mean corpuscular volume	82 fL
Platelets	200,000/mm^3
Leukocytes	9,000/mm^3
Urine β-hCG	Positive

Prior infection with which of the following microorganisms is most likely responsible for this patient's current condition?

- A. *Escherichia coli*
- B. *Gardnerella vaginalis*
- C. Herpes simplex virus
- D. Molluscum contagiosum virus
- E. *Neisseria gonorrhoeae*
- F. *Treponema pallidum*

follows:

Complete blood count	
Hemoglobin	12 g/dL
Mean corpuscular volume	82 fL
Platelets	200,000/mm^3
Leukocytes	9,000/mm^3
Urine β-hCG	Positive

Prior infection with which of the following microorganisms is most likely responsible for this patient's current condition?

- A. *Escherichia coli*
- B. *Gardnerella vaginalis*
- C. Herpes simplex virus
- D. Molluscum contagiosum virus
- E. *Neisseria gonorrhoeae*
- F. *Treponema pallidum*
- G. *Trichomonas vaginalis*

Submit

1 2 3 4 5 6 7 8 9 10 11 12 13 14 15 16 17 18 19 20 21 22 23 24 25 26 27 28 29 30

follows:

Complete blood count	
Hemoglobin	12 g/dL
Mean corpuscular volume	82 fL
Platelets	200,000/mm^3
Leukocytes	9,000/mm^3
Urine β-hCG	Positive

Prior infection with which of the following microorganisms is most likely responsible for this patient's current condition?

- A. *Escherichia coli* (3%)
- B. *Gardnerella vaginalis* (1%)
- C. Herpes simplex virus (2%)
- D. Molluscum contagiosum virus (1%)
- ✓ E. *Neisseria gonorrhoeae* (81%)
- F. *Treponema pallidum* (4%)
- G. *Trichomonas vaginalis* (4%)

Omitted
Correct answer

81%
Answered correctly

06 secs
Time Spent

06/29/2020
Last Updated

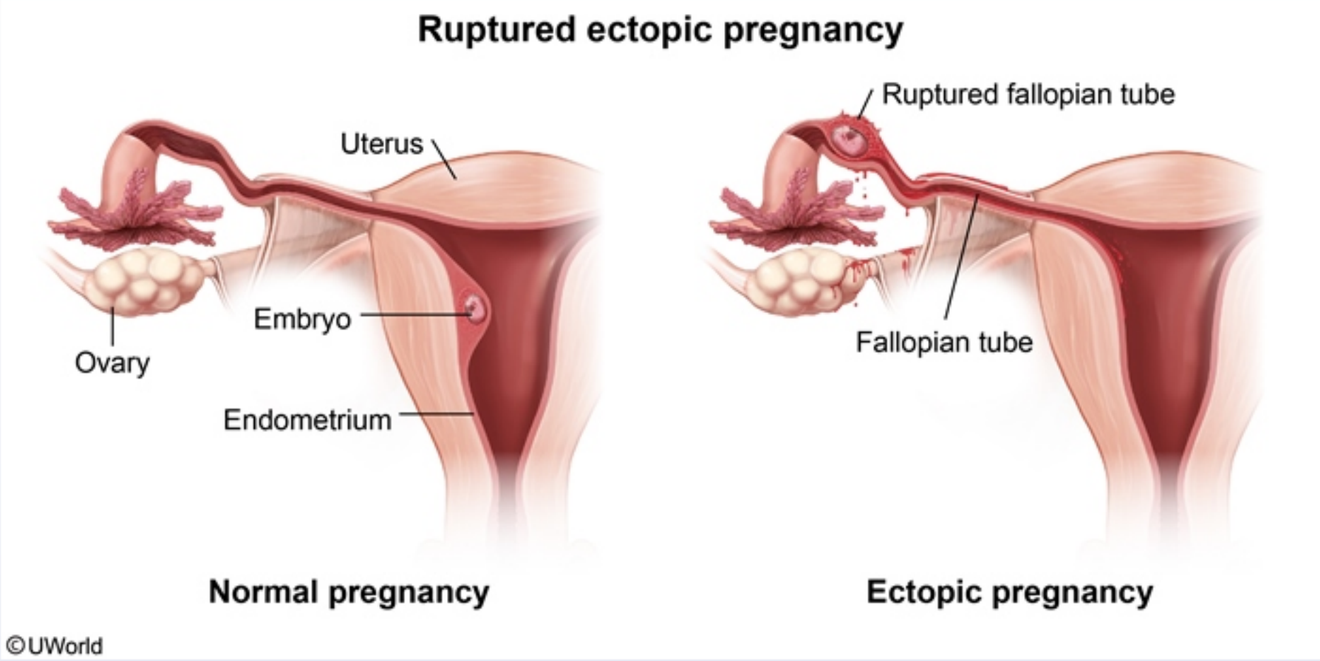

An ectopic pregnancy (EP) is nonviable as the gestational sac implants outside of the uterus. This patient's **abdominal pain, bloody vaginal discharge, orthostatic hypotension**, and positive pregnancy test are highly concerning for an **ectopic pregnancy** that may have ruptured.

The primary risk factor for an EP is **tubal scarring**. Prior infection with *Neisseria gonorrhoeae* and *Chlamydia trachomatis* are major predisposing factors as these microorganisms can cause inflammation and damage to the fallopian tubes and **pelvic inflammatory disease (PID)**. Disruption of tubal anatomy from surgery and sterilization are other risk factors for EP.

(Choice A) *Escherichia coli* is the most common cause of urinary tract infection. *E coli* is implicated in far fewer cases of PID compared to *N gonorrhoeae* and *C trachomatis*.

(Choices B and G) *Gardnerella vaginalis* is associated with bacterial vaginosis, whereas *Trichomonas vaginalis* is associated with trichomoniasis. These microbes typically affect the lower genital tract (vagina, vulva) and are not associated with PID.

An ectopic pregnancy (EP) is nonviable as the gestational sac implants outside of the uterus. This patient's **abdominal pain, bloody vaginal discharge, orthostatic hypotension**, and positive pregnancy test are highly concerning for an **ectopic pregnancy** that may have ruptured.

The primary risk factor for an EP is **tubal scarring**. Prior infection with *Neisseria gonorrhoeae* and *Chlamydia trachomatis* are major predisposing factors as these microorganisms can cause inflammation and damage to the fallopian tubes and **pelvic inflammatory disease (PID)**. Disruption of tubal anatomy from surgery and sterilization are other risk factors for EP.

(Choice A) *Escherichia coli* is the most common cause of urinary tract infection. *E coli* is implicated in far fewer cases of PID compared to *N gonorrhoeae* and *C trachomatis*.

(Choices B and G) *Gardnerella vaginalis* is associated with bacterial vaginosis, whereas *Trichomonas vaginalis* is associated with trichomoniasis. These microbes typically affect the lower genital tract (vagina, vulva) and are not associated with PID.

(Choice C) Herpes simplex virus is associated with genital herpes, not PID.

(Choice D) Molluscum contagiosum virus is associated with a chronic, localized infection in which firm, dome-shaped, umbilicated papules erupt on the skin. This poxvirus is not associated with PID.

(Choice F) *Treponema pallidum* is a bacterium that causes syphilis. Clinical manifestations include a firm, round, painless chancre at the location where the bacterium entered the body. PID is not associated with syphilis.

Educational objective:
Ruptured ectopic pregnancy can cause abdominal pain, vaginal bleeding, and hemodynamic instability. Pelvic inflammatory disease is most commonly caused by *Neisseria gonorrhoeae* or *Chlamydia trachomatis* and significantly increases the risk of ectopic pregnancy.

References

- Clinical diagnosis and treatment of ectopic pregnancy.
- Chlamydia trachomatis infection increases fallopian tube PROKR2 via TLR2 and NF?B activation resulting in a microenvironment predisposed to ectopic pregnancy.

Microbiology Female Reproductive System & Breast Pelvic inflammatory disease

factors as these microorganisms can cause inflammation and damage to the fallopian tubes and **pelvic inflammatory disease (PID)**. Disruption of tubal anatomy from surgery and sterilization are other risk factors for EP.

(Choice A) *Escherichia coli* is the most common cause of urinary tract infection. *E coli* is implicated in far fewer cases of PID compared to *N gonorrhoeae* and *C trachomatis*.

(Choices B and G) *Gardnerella vaginalis* is associated with bacterial vaginosis, whereas *Trichomonas vaginalis* is associated with trichomoniasis. These microbes typically affect the lower genital tract (vagina, vulva) and are not associated with PID.

(Choice C) Herpes simplex virus is associated with genital herpes, not PID.

(Choice D) Molluscum contagiosum virus is associated with a chronic, localized infection in which firm, dome-shaped, umbilicated papules erupt on the skin. This poxvirus is not associated with PID.

(Choice F) *Treponema pallidum* is a bacterium that causes syphilis. Clinical manifestations include a firm, round, painless chancre at the location where the bacterium entered the body. PID is not associated with syphilis.

Educational objective:
Ruptured ectopic pregnancy can cause abdominal pain, vaginal bleeding, and hemodynamic instability. Pelvic inflammatory disease is most commonly caused by *Neisseria gonorrhoeae* or *Chlamydia trachomatis* and significantly increases the risk of ectopic pregnancy.

References

- Clinical diagnosis and treatment of ectopic pregnancy.
- Chlamydia trachomatis infection increases fallopian tube PROKR2 via TLR2 and NF?B activation resulting in a microenvironment predisposed to ectopic pregnancy.

Microbiology	Female Reproductive System & Breast	Pelvic inflammatory disease
Subject	System	Topic

Copyright © UWorld. All rights reserved.

Settings

1
2
3
4
5
6
7
8
9
10
11
12
13
14
15
16
17
18
19
20
21
22
23
24
25
26
27
28
29
30

Item 23 of 33
Question Id: 1932

Mark | Previous | Next | Full Screen | Tutorial | Lab Values | Notes | Calculator | Reverse Color | Text Zoom | Settings

factors as these microorganisms can cause inflammation and damage to the fallopian tubes and **pelvic inflammatory disease (PID)**. Disruption

Exhibit Display

Zoom In | Zoom Out | Reset | Add To New Card | Existing Card

Block Time Remaining: 00:01:13
TUTOR

4 | Feedback | Suspend | End Block

Settings

1
2
3
4
5
6
7
8
9
10
11
12
13
14
15
16
17
18
19
20
21
22
23
24
25
26
27
28
29
30

Item 23 of 33
Question Id: 1932

Mark | Previous | Next | Full Screen | Tutorial | Lab Values | Notes | Calculator | Reverse Color | Text Zoom | Settings

factors as these microorganisms can cause inflammation and damage to the fallopian tubes and **pelvic inflammatory disease (PID)**. Disruption

Exhibit Display

Zoom In | Zoom Out | Reset | Add To New Card | Existing Card

Block Time Remaining: 00:01:13
TUTOR

4 | Feedback | Suspend | End Block

A 22-year-old woman comes to the emergency department with dysuria, vulvar pain, and itching. She has felt feverish and fatigued for the last few days. She has a new sexual partner and has been using a hormonal vaginal ring to prevent pregnancy. The patient had chlamydia 3 years ago and was treated with antibiotics. Physical examination reveals inguinal lymphadenopathy and tender vesicular lesions covering both labia majora and the perineum. This patient's infection can lead to which of the following conditions?

- A. Facial nerve palsy
- B. Locomotor ataxia
- C. Postherpetic neuralgia
- D. Recurrent genital ulcers
- E. Squamous cell vulvar carcinoma

Submit

A 22-year-old woman comes to the emergency department with dysuria, vulvar pain, and itching. She has felt feverish and fatigued for the last few days. She has a new sexual partner and has been using a hormonal vaginal ring to prevent pregnancy. The patient had chlamydia 3 years ago and was treated with antibiotics. Physical examination reveals inguinal lymphadenopathy and tender vesicular lesions covering both labia majora and the perineum. This patient's infection can lead to which of the following conditions?

- A. Facial nerve palsy (1%)
- B. Locomotor ataxia (2%)
- C. Postherpetic neuralgia (16%)
- ✓ D. Recurrent genital ulcers (68%)
- E. Squamous cell vulvar carcinoma (10%)

Omitted
Correct answer
D

68%
Answered correctly

02 secs
Time Spent

02/03/2020
Last Updated

Explanation

Genital herpes	
Etiology	HSV-2 (most common)
Clinical presentation	• Cluster of painful vesicles, pustules &/or ulcers on labia, penis, buttocks, or thigh • ± Systemic symptoms in primary infection

Genital herpes	
Etiology	HSV-2 (most common)
Clinical presentation	• Cluster of painful vesicles, pustules &/or ulcers on labia, penis, buttocks, or thigh • ± Systemic symptoms in primary infection
Treatment	Acyclovir, famciclovir, or valacyclovir

HSV = herpes simplex virus.

Herpes is one of the most common **sexually transmitted** diseases. This patient's systemic symptoms (eg, **fever**, myalgia); **inguinal lymphadenopathy**; and itchy, painful, vesicular genital rash are typical of **primary genital herpes**. Genital herpes is most commonly caused by **herpes virus type 2 (HSV-2)**. The characteristic rash on the genitalia or buttocks occurs in stages - **vesicles, ulcers**, and then **crusting**.

Following infection, HSV lies dormant in the sacral dorsal root ganglia and can be reactivated to cause **recurrent genital lesions**. Recurrence tends to be localized and less severe due to humoral immunity from prior infection. Patients are more contagious during a recurrence, and barrier contraception prevents spread.

(Choice A) Facial nerve palsy can be a neurological manifestation of Lyme disease (caused by the spirochete *Borrelia burgdorferi*) or HSV-1. HSV-1 typically causes oral rather than genital vesicles. Lyme disease typically causes fatigue, anorexia, headache, and occasional fever, without a vesicular rash.

(Choice B) Untreated syphilis can infect the dorsal roots of the spinal column and lead to tertiary neurosyphilis characterized by tabes dorsalis (locomotor ataxia) and general paresis. Primary syphilis typically presents with a single painless genital lesion (chancre) after initial infection with *Treponema pallidum* spirochete.

(Choice C) Varicella zoster virus also invades the dorsal root sensory ganglia, and reactivation from the dorsal root ganglia causes herpes zoster (eg, shingles). A complication of shingles is postherpetic neuralgia (persistent pain after resolution of lesions). Typical presentation of herpes zoster is a painful vesicular rash in a dermatomal distribution without systemic involvement, in contrast to this patient with bilateral vesicular

Settings

1 2 3 4 5 6 7 8 9 10 11 12 13 14 15 16 17 18 19 20 21 22 23 24 25 26 27 28 29 30

Item 24 of 33
Question Id: 1549

Mark | Previous | Next | Full Screen | Tutorial | Lab Values | Notes | Calculator | Reverse Color | Text Zoom | Settings

Genital herpes

Exhibit Display

Zoom In | Zoom Out | Reset | Add To New Card | Existing Card

(Choice E) Human papillomavirus is an oncogenic double-stranded DNA virus that exclusively infects the epithelial cells, predisposing to the

Block Time Remaining: 00:01:15
TUTOR

5 | Feedback | Suspend | End Block

Settings

1 2 3 4 5 6 7 8 9 10 11 12 13 14 15 16 17 18 19 20 21 22 23 24 25 26 27 28 29 30

Item 24 of 33
Question Id: 1549

Mark | Previous | Next | Full Screen | Tutorial | Lab Values | Notes | Calculator | Reverse Color | Text Zoom | Settings

Herpes is one of the most common **sexually transmitted** diseases. This patient's systemic symptoms (eg, **fever**, myalgia), **inguinal lymphadenopathy**, and itchy, painful, vesicular genital rash are typical of primary genital herpes. Genital herpes is most commonly caused by

Exhibit Display

Zoom In | Zoom Out | Reset | Add To New Card | Existing Card

- Genital herpes.

Block Time Remaining: 00:01:15
TUTOR

5 | Feedback | Suspend | End Block

contraception prevents spread.

(Choice A) Facial nerve palsy can be a neurological manifestation of Lyme disease (caused by the spirochete *Borrelia burgdorferi*) or HSV-1. HSV-1 typically causes oral rather than genital vesicles. Lyme disease typically causes fatigue, anorexia, headache, and occasional fever, without a vesicular rash.

(Choice B) Untreated syphilis can infect the dorsal roots of the spinal column and lead to tertiary neurosyphilis characterized by tabes dorsalis (locomotor ataxia) and general paresis. Primary syphilis typically presents with a single painless genital lesion (chancre) after initial infection with *Treponema pallidum* spirochete.

(Choice C) Varicella zoster virus also invades the dorsal root sensory ganglia, and reactivation from the dorsal root ganglia causes herpes zoster (eg, shingles). A complication of shingles is postherpetic neuralgia (persistent pain after resolution of lesions). Typical presentation of herpes zoster is a painful vesicular rash in a dermatomal distribution without systemic involvement, in contrast to this patient with bilateral vesicular lesions and fever.

(Choice E) Human papillomavirus is an oncogenic double-stranded DNA virus that exclusively infects the epithelial cells, predisposing to the development of cervical and vulvar carcinoma. Warts are the most common skin manifestation.

Educational objective:
Primary infection with herpes simplex virus type 2 (HSV-2) typically presents with fever and a painful vesicular genital rash. HSV-2 primarily infects the sacral dorsal root ganglia and can be reactivated to cause recurrent genital lesions.

References

- Current concepts for genital herpes simplex virus infection: diagnostics and pathogenesis of genital tract shedding.
- Genital herpes.

Microbiology	Female Reproductive System & Breast	HSV infection
Subject	System	Topic

Copyright © UWorld. All rights reserved.

A 62-year-old man comes to the emergency department due to 3 days of severe sore throat, difficulty swallowing, and hoarseness. He has no chronic medical conditions but has not seen a physician for many years. The patient received recommended childhood vaccinations but has had none since then. He is a farmer and has not traveled recently but has been in contact with migrant farmworkers. Temperature is 38.3 C (101 F), blood pressure is 110/60 mm Hg, and pulse is 116/min. Physical examination reveals pharyngeal erythema and edema with coalescing, gray exudate. Bilateral cervical lymph nodes are enlarged and tender. A rapid streptococcal test result is negative. Throat swab culture grows non-spore–forming, gram-positive rods. Which of the following is most helpful in preventing the systemic complications of this infection in this patient?

- A. Airway edema reduction with inhaled epinephrine
- B. Antibiotics administration to kill bacteria within the bloodstream
- C. Blunting the immune response with glucocorticoids
- D. Preformed antibody administration to bind bacterial product
- E. Vaccination with inactivated bacterial toxin

Submit

A 62-year-old man comes to the emergency department due to 3 days of severe sore throat, difficulty swallowing, and hoarseness. He has no chronic medical conditions but has not seen a physician for many years. The patient received recommended childhood vaccinations but has had none since then. He is a farmer and has not traveled recently but has been in contact with migrant farmworkers. Temperature is 38.3 C (101 F), blood pressure is 110/60 mm Hg, and pulse is 116/min. Physical examination reveals pharyngeal erythema and edema with coalescing, gray exudate. Bilateral cervical lymph nodes are enlarged and tender. A rapid streptococcal test result is negative. Throat swab culture grows non-spore–forming, gram-positive rods. Which of the following is most helpful in preventing the systemic complications of this infection in this patient?

- A. Airway edema reduction with inhaled epinephrine (2%)
- B. Antibiotics administration to kill bacteria within the bloodstream (19%)
- C. Blunting the immune response with glucocorticoids (2%)
- ✓ D. Preformed antibody administration to bind bacterial product (45%)
- E. Vaccination with inactivated bacterial toxin (29%)

Omitted
Correct answer
D

45%
Answered correctly

02 secs
Time Spent

02/07/2020
Last Updated

Explanation

Diphtheria	
Epidemiology	• Rare in developed countries due to widespread vaccination

Diphtheria	
Epidemiology	• Rare in developed countries due to widespread vaccination • Risk: inadequate vaccination/10-year booster shot
Pathogenesis	• **Toxigenic *Corynebacterium diphtheriae*** colonizes respiratory tract → secretes **diphtheria toxin** → inhibits host protein synthesis (ADP-ribosylation of EF-2) → local and systemic toxin-mediated effects
Manifestations	• Local: **pseudomembranous pharyngitis**, cervical LAD • Systemic: **myocarditis**/heart failure, neurologic toxicity • Pharyngeal edema/pseudomembrane spread can obstruct respiratory tract
Treatment	• **Diphtheria antitoxin** (most important) • Antibiotics

EF-2 = elongation factor-2; LAD = lymphadenopathy.

Diphtheria is caused by infection with toxigenic strains of *Corynebacterium diphtheriae*, a non-spore–forming, gram-positive rod that is transmitted by aerosolized droplets. Cases are rare in the United States due to widespread vaccination efforts. However, infections can occur in those who received inadequate childhood vaccines or those who did not receive booster vaccination every 10 years.

The manifestations of diphtheria are due to the elaboration of **diphtheria toxin** (DT), an exotoxin that **irreversibly inhibits host protein synthesis** by ADP-ribosylation of elongation factor-2. Local effects include pharyngitis and tonsillitis, often with thick, **grey-white pseudomembranes**. Systemic effects are caused by the absorption of DT into the bloodstream and include potentially life-threatening cardiac (eg, myocarditis) and neurologic complications.

The primary treatment for diphtheria is the urgent administration of **diphtheria antitoxin**, which contains **preformed**, **neutralizing antibodies** that binds and inactivates circulating toxin. Because it cannot inhibit the toxin that has already entered cells, it should be administered as soon as possible. Antibiotic therapy (eg, penicillin, erythromycin) is also given to reduce continued elaboration of DT from the nasopharyngeal infection.

Diphtheria is caused by infection with toxigenic strains of *Corynebacterium diphtheriae*, a non-spore–forming, gram-positive rod that is transmitted by aerosolized droplets. Cases are rare in the United States due to widespread vaccination efforts. However, infections can occur in those who received inadequate childhood vaccines or those who did not receive booster vaccination every 10 years.

The manifestations of diphtheria are due to the elaboration of **diphtheria toxin** (DT), an exotoxin that **irreversibly inhibits host protein synthesis** by ADP-ribosylation of elongation factor-2. Local effects include pharyngitis and tonsillitis, often with thick, **grey-white pseudomembranes**. Systemic effects are caused by the absorption of DT into the bloodstream and include potentially life-threatening cardiac (eg, myocarditis) and neurologic complications.

The primary treatment for diphtheria is the urgent administration of **diphtheria antitoxin**, which contains **preformed**, **neutralizing antibodies** that binds and inactivates circulating toxin. Because it cannot inhibit the toxin that has already entered cells, it should be administered as soon as possible. Antibiotic therapy (eg, penicillin, erythromycin) is also given to reduce continued elaboration of DT from the nasopharyngeal infection.

(Choice A) Inhaled, racemic epinephrine can be used in the treatment of croup, which usually presents with cough, inspiratory stridor, and/or hoarseness. Epinephrine could reduce airway swelling in patients with diphtheria, but it would not inhibit the local and systemic effects of the toxin.

(Choice B) *C diphtheriae* is noninvasive and does not typically enter the bloodstream. Although antibiotics are administered in acute infection, this component of therapy is less important than providing antitoxin to neutralize DT.

(Choice C) Corticosteroids are sometimes used in the treatment of epiglottitis to reduce airway inflammation and limit the risk of airway compromise. Epiglottitis manifestations typically include stridor, drooling, respiratory distress, and the assumption of the "tripod" position. Most cases are caused by infection with *Haemophilus influenzae* type B in unvaccinated individuals.

(Choice E) Active immunization with the diphtheria toxoid (given as part of the childhood DTaP vaccine) prevents diphtheria. Diphtheria toxoid can also be given as part of tetanus boosters in adults. However, the immune response to vaccination is slow; in undervaccinated patients who are acutely ill, administration of preformed antitoxin antibodies is preferred.

Educational objective:
The primary treatment for diphtheria is diphtheria antitoxin (passive immunization), which inactivates circulating toxin. Antibiotics should also be

pseudomembranes. Systemic effects are caused by the absorption of DT into the bloodstream and include potentially life-threatening cardiac (eg, myocarditis) and neurologic complications.

The primary treatment for diphtheria is the urgent administration of **diphtheria antitoxin**, which contains **preformed**, **neutralizing antibodies** that binds and inactivates circulating toxin. Because it cannot inhibit the toxin that has already entered cells, it should be administered as soon as possible. Antibiotic therapy (eg, penicillin, erythromycin) is also given to reduce continued elaboration of DT from the nasopharyngeal infection.

(Choice A) Inhaled, racemic epinephrine can be used in the treatment of croup, which usually presents with cough, inspiratory stridor, and/or hoarseness. Epinephrine could reduce airway swelling in patients with diphtheria, but it would not inhibit the local and systemic effects of the toxin.

(Choice B) *C diphtheriae* is noninvasive and does not typically enter the bloodstream. Although antibiotics are administered in acute infection, this component of therapy is less important than providing antitoxin to neutralize DT.

(Choice C) Corticosteroids are sometimes used in the treatment of epiglottitis to reduce airway inflammation and limit the risk of airway compromise. Epiglottitis manifestations typically include stridor, drooling, respiratory distress, and the assumption of the "tripod" position. Most cases are caused by infection with *Haemophilus influenzae* type B in unvaccinated individuals.

(Choice E) Active immunization with the diphtheria toxoid (given as part of the childhood DTaP vaccine) prevents diphtheria. Diphtheria toxoid can also be given as part of tetanus boosters in adults. However, the immune response to vaccination is slow; in undervaccinated patients who are acutely ill, administration of preformed antitoxin antibodies is preferred.

Educational objective:
The primary treatment for diphtheria is diphtheria antitoxin (passive immunization), which inactivates circulating toxin. Antibiotics should also be administered to reduce continued production of toxin.

References

- Diphtheria remains a threat to health in the developing world—an overview.
- Clinical characteristics and management of 676 hospitalized diphtheria cases, Kyrgyz Republic, 1995.

Microbiology Allergy & Immunology Diphtheria

1 2 3 4 5 6 7 8 9 10 11 12 13 14 15 16 17 18 19 20 21 22 23 24 25 26 27 28 29 30

binds and inactivates circulating toxin. Because it cannot inhibit the toxin that has already entered cells, it should be administered as soon as possible. Antibiotic therapy (eg, penicillin, erythromycin) is also given to reduce continued elaboration of DT from the nasopharyngeal infection.

(Choice A) Inhaled, racemic epinephrine can be used in the treatment of croup, which usually presents with cough, inspiratory stridor, and/or hoarseness. Epinephrine could reduce airway swelling in patients with diphtheria, but it would not inhibit the local and systemic effects of the toxin.

(Choice B) *C diphtheriae* is noninvasive and does not typically enter the bloodstream. Although antibiotics are administered in acute infection, this component of therapy is less important than providing antitoxin to neutralize DT.

(Choice C) Corticosteroids are sometimes used in the treatment of epiglottitis to reduce airway inflammation and limit the risk of airway compromise. Epiglottitis manifestations typically include stridor, drooling, respiratory distress, and the assumption of the "tripod" position. Most cases are caused by infection with *Haemophilus influenzae* type B in unvaccinated individuals.

(Choice E) Active immunization with the diphtheria toxoid (given as part of the childhood DTaP vaccine) prevents diphtheria. Diphtheria toxoid can also be given as part of tetanus boosters in adults. However, the immune response to vaccination is slow; in undervaccinated patients who are acutely ill, administration of preformed antitoxin antibodies is preferred.

Educational objective:
The primary treatment for diphtheria is diphtheria antitoxin (passive immunization), which inactivates circulating toxin. Antibiotics should also be administered to reduce continued production of toxin.

References

- Diphtheria remains a threat to health in the developing world—an overview.
- Clinical characteristics and management of 676 hospitalized diphtheria cases, Kyrgyz Republic, 1995.

Microbiology	Allergy & Immunology	Diphtheria
Subject	System	Topic

Copyright © UWorld. All rights reserved.

A 28-year-old man comes to the office due to a rash on the lower extremity. The patient noticed a pruritic papule on the dorsum of his right foot just prior to returning from a south Florida beach 2 days ago. He walked barefoot on the beach but does not recall any trauma. Since his return home, the rash and itching have progressively worsened. The patient has no other medical problems and takes no medications. Physical examination findings are shown below.

Which of the following is the most likely cause of this patient's current condition?

- A. Brown recluse spider bite
- B. Hookworm infection
- C. *Mycobacterium marinum* infection
- D. *Sporothrix schenckii* infection
- E. *Staphylococcus aureus* infection
- F. *Vibrio vulnificus* infection

Submit

1 2 3 4 5 6 7 8 9 10 11 12 13 14 15 16 17 18 19 20 21 22 23 24 25 26 27 28 29 30

Which of the following is the most likely cause of this patient's current condition?

- A. Brown recluse spider bite (2%)
- ✓ B. Hookworm infection (72%)
- C. *Mycobacterium marinum* infection (7%)
- D. *Sporothrix schenckii* infection (5%)
- E. *Staphylococcus aureus* infection (1%)
- F. *Vibrio vulnificus* infection (10%)

Omitted
Correct answer

72%
Answered correctly

05 secs
Time Spent

04/23/2020
Last Updated

This patient, who developed a serpiginous, pruritic rash shortly after walking barefoot on a beach, likely has **hookworm infection**. Hookworms spread when **egg-containing feces** are deposited into shady, warm, moist sand or soil. Eggs hatch into larvae and are transmitted when they come into **direct contact with human skin** (eg, when walking barefoot).

Dermal penetration is usually marked by a **pruritic maculopapular lesion** ("ground itch") at the site of larval entry (eg, foot, toe webs). Spread of larvae through the adjacent dermal tissue can lead to the formation of migrating, reddish-brown, **serpiginous tracks**. Deeper spread may occur, depending on the species of infecting hookworm, as follows:

- Human hookworms (eg, *Necator americanus*, *A duodenale*) penetrate the basement membrane and spread from the dermis to the bloodstream. They rupture into the alveoli and are coughed up and swallowed into the small intestine. There, larvae mature into adult hookworms that feed on blood from the duodenal mucosa (often causing iron deficiency anemia) and shed up to 10,000 eggs/day, thereby spreading the infection to others.
- Cat and dog hookworms (eg, *Ancylostoma braziliense*, *A caninum*) cause a dermal eruption in humans but are unable to penetrate the cutaneous basement membrane and spread to deeper tissues. Therefore, larvae do not mature into adult hookworms or spread from human-to-human (humans are incidental hosts).

(Choice A) A brown recluse spider bite usually appears as a red plaque or papule with central pallor; it may develop a dark central eschar that ulcerates due to necrosis. Pain is often severe.

(Choice C) *Mycobacterium marinum* lesions usually form a few weeks after exposure to contaminated fresh/salt water (eg, swimming pool, fish tank). Lesions begin as solitary papules or nodules that eventually ulcerate and scar. Serpiginous tracts would be uncommon.

(Choice D) *Sporothrix schenckii*, a dimorphic fungus, is usually transmitted when contaminated organic material (eg, moss, soil) is inoculated into the skin or subcutaneous tissue. A papule forms at the inoculation site and usually ulcerates; additional lesions form along the proximal route of lymphatic drainage.

(Choice E) *Staphylococcus aureus* is the most common cause of purulent cellulitis. Lesions tend to develop over days and are characterized by painful areas of fluctuance with surrounding erythema.

(Choice F) *Vibrio vulnificus* is a free-living bacterium that grows in brackish water and marine environments. It can contaminate wounds and cause mild cellulitis. More severe manifestations (eg, myositis, necrotizing fasciitis, sepsis) can develop in patients with certain underlying

depending on the species of infecting hookworm, as follows:

- Human hookworms (eg, *Necator americanus*, *A duodenale*) penetrate the basement membrane and spread from the dermis to the bloodstream. They rupture into the alveoli and are coughed up and swallowed into the small intestine. There, larvae mature into adult hookworms that feed on blood from the duodenal mucosa (often causing iron deficiency anemia) and shed up to 10,000 eggs/day, thereby spreading the infection to others.
- Cat and dog hookworms (eg, *Ancylostoma braziliense*, *A caninum*) cause a dermal eruption in humans but are unable to penetrate the cutaneous basement membrane and spread to deeper tissues. Therefore, larvae do not mature into adult hookworms or spread from human-to-human (humans are incidental hosts).

(Choice A) A brown recluse spider bite usually appears as a red plaque or papule with central pallor; it may develop a dark central eschar that ulcerates due to necrosis. Pain is often severe.

(Choice C) *Mycobacterium marinum* lesions usually form a few weeks after exposure to contaminated fresh/salt water (eg, swimming pool, fish tank). Lesions begin as solitary papules or nodules that eventually ulcerate and scar. Serpiginous tracts would be uncommon.

(Choice D) *Sporothrix schenckii*, a dimorphic fungus, is usually transmitted when contaminated organic material (eg, moss, soil) is inoculated into the skin or subcutaneous tissue. A papule forms at the inoculation site and usually ulcerates; additional lesions form along the proximal route of lymphatic drainage.

(Choice E) *Staphylococcus aureus* is the most common cause of purulent cellulitis. Lesions tend to develop over days and are characterized by painful areas of fluctuance with surrounding erythema.

(Choice F) *Vibrio vulnificus* is a free-living bacterium that grows in brackish water and marine environments. It can contaminate wounds and cause mild cellulitis. More severe manifestations (eg, myositis, necrotizing fasciitis, sepsis) can develop in patients with certain underlying comorbidities (eg, liver disease, hemochromatosis).

Educational objective:
Hookworm infections are transmitted via direct contact between human skin and contaminated soil/sand (eg, walking barefoot). Dermal penetration is often characterized by an intensely pruritic papule that may form serpiginous tracks due to the subcutaneous migration of hookworm

- Cat and dog hookworms (eg, *Ancylostoma braziliense*, *A caninum*) cause a dermal eruption in humans but are unable to penetrate the cutaneous basement membrane and spread to deeper tissues. Therefore, larvae do not mature into adult hookworms or spread from human-to-human (humans are incidental hosts).

(Choice A) A brown recluse spider bite usually appears as a red plaque or papule with central pallor; it may develop a dark central eschar that ulcerates due to necrosis. Pain is often severe.

(Choice C) *Mycobacterium marinum* lesions usually form a few weeks after exposure to contaminated fresh/salt water (eg, swimming pool, fish tank). Lesions begin as solitary papules or nodules that eventually ulcerate and scar. Serpiginous tracts would be uncommon.

(Choice D) *Sporothrix schenckii*, a dimorphic fungus, is usually transmitted when contaminated organic material (eg, moss, soil) is inoculated into the skin or subcutaneous tissue. A papule forms at the inoculation site and usually ulcerates; additional lesions form along the proximal route of lymphatic drainage.

(Choice E) *Staphylococcus aureus* is the most common cause of purulent cellulitis. Lesions tend to develop over days and are characterized by painful areas of fluctuance with surrounding erythema.

(Choice F) *Vibrio vulnificus* is a free-living bacterium that grows in brackish water and marine environments. It can contaminate wounds and cause mild cellulitis. More severe manifestations (eg, myositis, necrotizing fasciitis, sepsis) can develop in patients with certain underlying comorbidities (eg, liver disease, hemochromatosis).

Educational objective:
Hookworm infections are transmitted via direct contact between human skin and contaminated soil/sand (eg, walking barefoot). Dermal penetration is often characterized by an intensely pruritic papule that may form serpiginous tracks due to the subcutaneous migration of hookworm larvae.

Microbiology	Dermatology	Cutaneous larva migrans
Subject	System	Topic

Copyright © UWorld. All rights reserved.

Exhibit Display

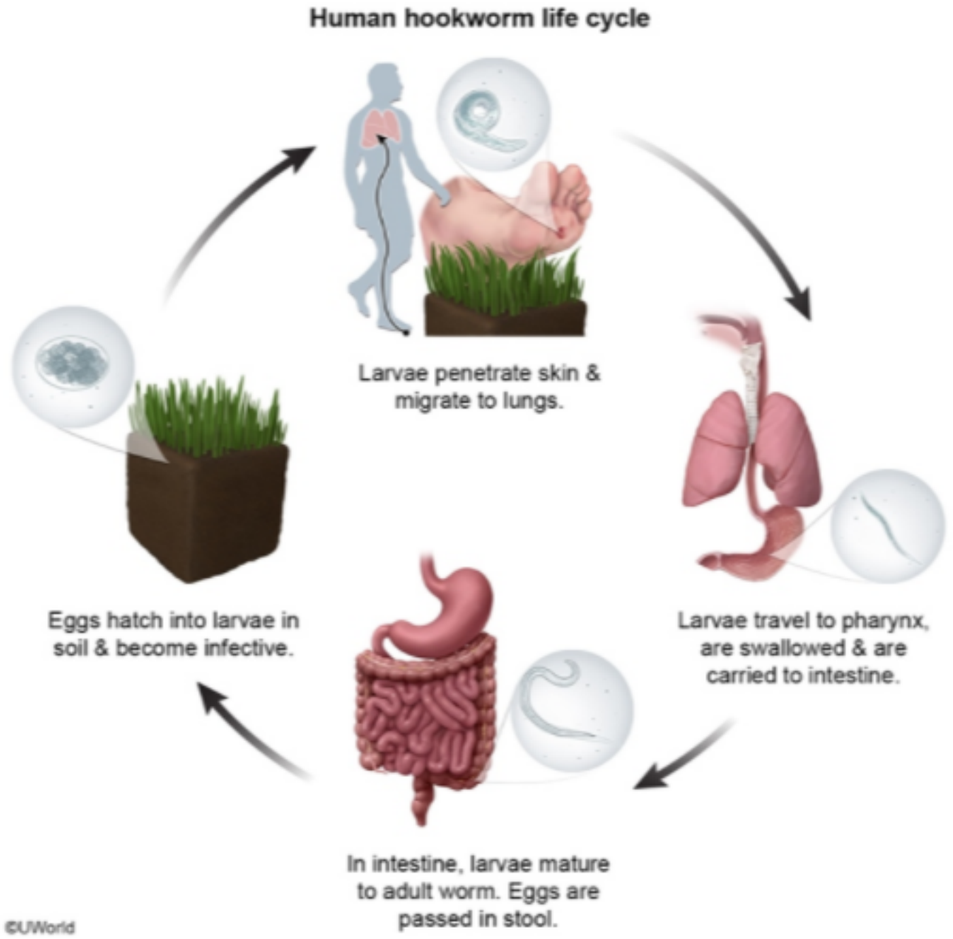

Zoom In | Zoom Out | Reset | Add To New Card | Existing Card

tank). Lesions begin as solitary papules or nodules that eventually ulcerate and scar. Serpiginous tracts would be uncommon.

A 65-year-old man is admitted to the intensive care unit with second- and third-degree burns over 25% of his total body surface area. Intravenous fluids and analgesics are administered, and his wounds are cleaned and debrided. After 7 days, the patient develops a fever and his leukocyte count rises to 16,000 cells/μL. Examination of the burns on his left leg shows surrounding warmth, erythema, and induration. Gram stain of his wound tissue is shown in the image below.

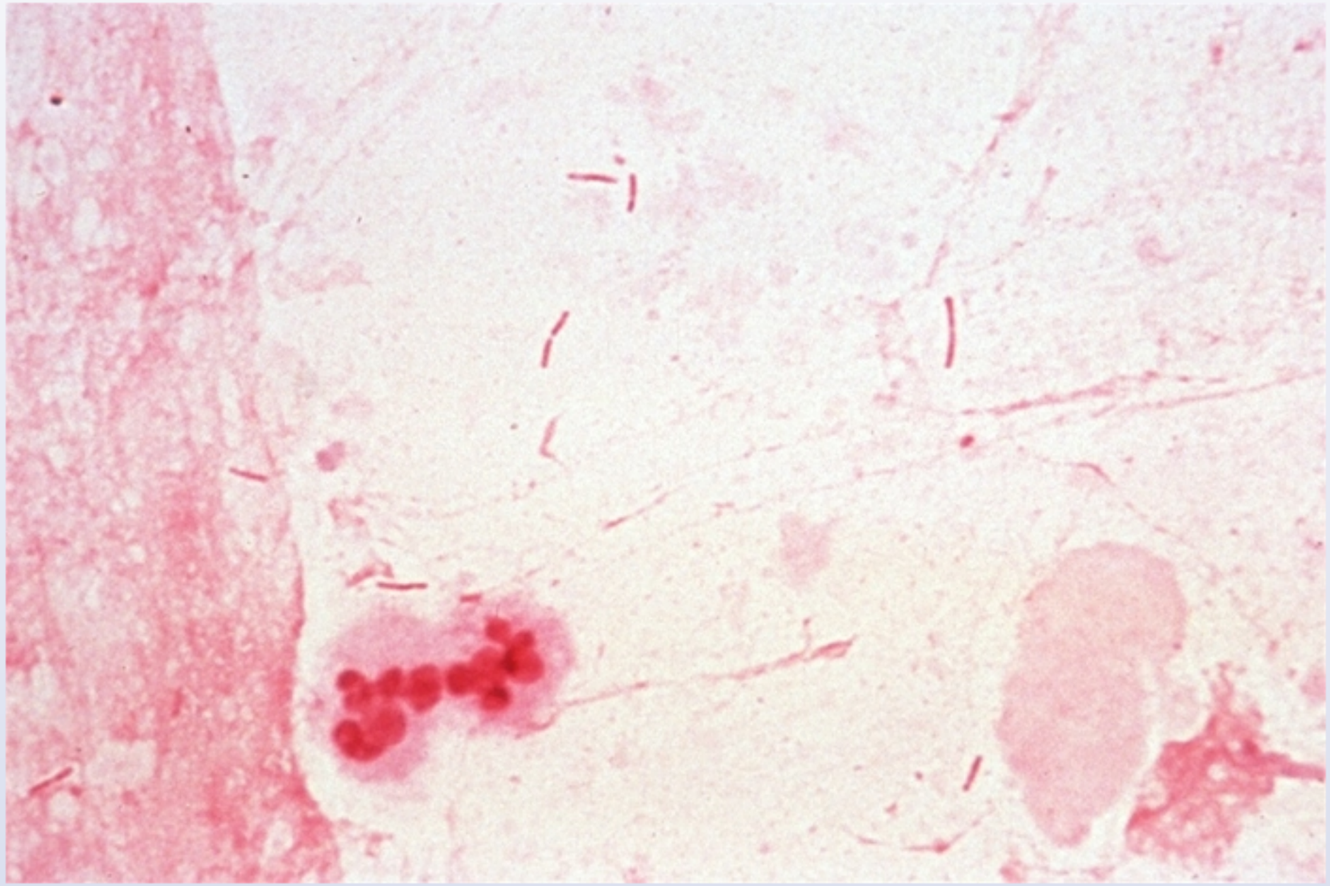

Culture on MacConkey agar grows oxidase-positive colonies that do not ferment lactose. Which of the following is the best initial treatment for this

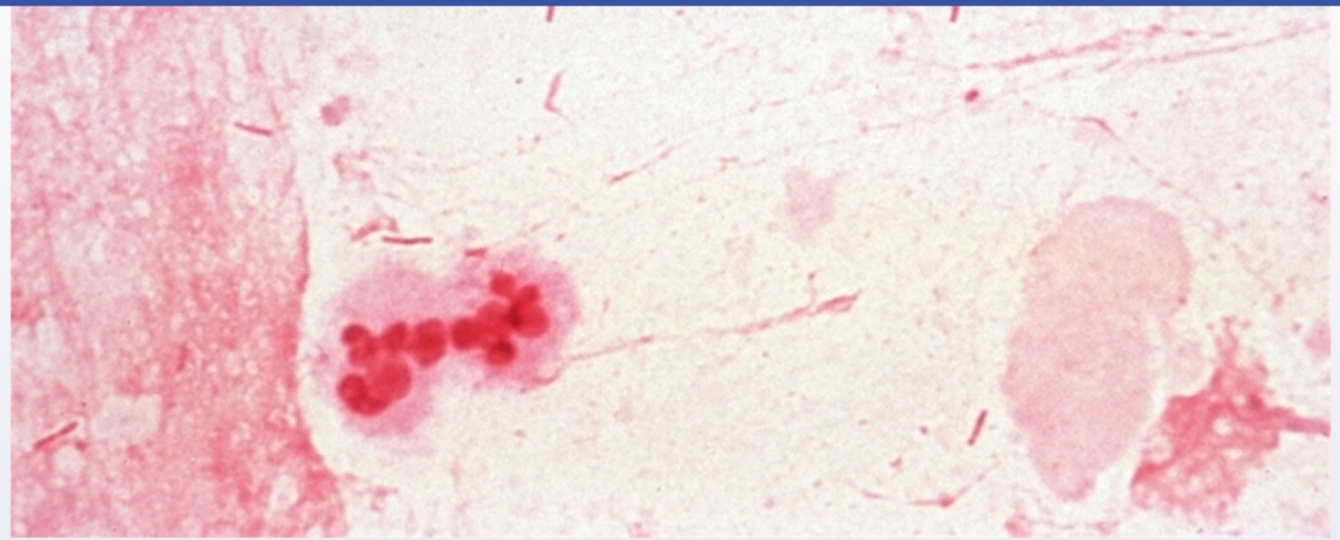

Culture on MacConkey agar grows oxidase-positive colonies that do not ferment lactose. Which of the following is the best initial treatment for this patient?

A. Cefepime
B. Ceftriaxone
C. Doxycycline
D. Moxifloxacin
E. Trimethoprim-sulfamethoxazole

Submit

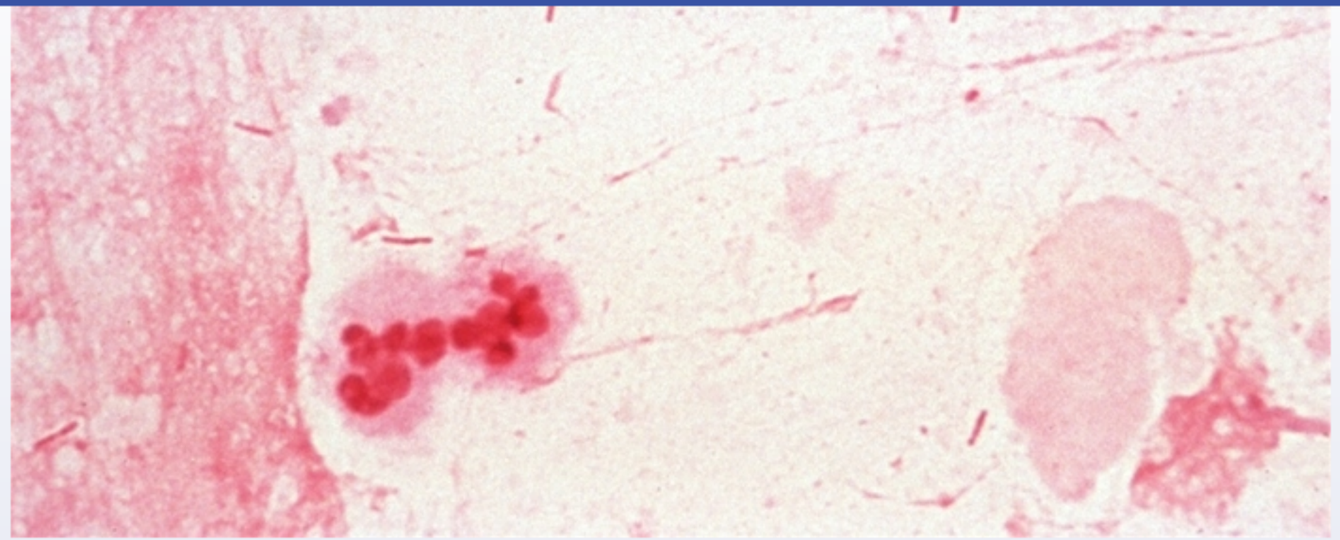

Culture on MacConkey agar grows oxidase-positive colonies that do not ferment lactose. Which of the following is the best initial treatment for this patient?

- ✓ A. Cefepime (45%)
- B. Ceftriaxone (23%)
- C. Doxycycline (7%)
- D. Moxifloxacin (15%)
- E. Trimethoprim-sulfamethoxazole (8%)

Omitted
Correct answer

45%
Answered correctly

06 secs
Time Spent

03/13/2020
Last Updated

Antibiotics effective against *Pseudomonas aeruginosa*

Class	Drugs
Anti-pseudomonal penicillins	• Ticarcillin • Piperacillin
Cephalosporins	• Ceftazidime (3rd generation) • Cefepime (4th generation)
Aminoglycosides	• Amikacin • Gentamicin • Tobramycin
Fluoroquinolones	• Ciprofloxacin • Levofloxacin
Monobactams	• Aztreonam
Carbapenems	• Imipenem • Meropenem

©UWorld

Burn patients are at increased risk of bacterial infection due to loss of the barrier function of the skin, post-burn immune dysfunction, and lack of blood flow to necrotic areas. Common pathogens include Gram-positive (eg, *Staphylococcus aureus*, *Enterococcus* species) and Gram-negative

Burn patients are at increased risk of bacterial infection due to loss of the barrier function of the skin, post-burn immune dysfunction, and lack of blood flow to necrotic areas. Common pathogens include Gram-positive (eg, *Staphylococcus aureus*, *Enterococcus* species) and Gram-negative (eg, *Pseudomonas aeruginosa*, *Escherichia coli*, *Klebsiella pneumoniae*, and *Acinetobacter* species) bacteria.

This patient's burn is infected with Gram-negative rods that are oxidase-positive and non-lactose- fermenting, making *P aeruginosa* the most likely pathogen. Cephalosporins such as cefepime and ceftazidime have good anti-pseudomonal coverage.

(Choice B) Ceftriaxone is a third-generation cephalosporin used primarily for the treatment of community-acquired pneumonia and bacterial meningitis. It has activity against some Gram-positive (eg, *Streptococcus pneumoniae*, *S pyogenes*) and Gram-negative (eg, *Haemophilus influenzae*, *K pneumoniae*, *E coli*) pathogens. Unlike ceftazidime, it has poor activity against *P aeruginosa*.

(Choice C) Doxycycline is effective against Lyme disease and many tickborne rickettsial diseases but does not have good anti-pseudomonal coverage.

(Choice D) Moxifloxacin is a fluoroquinolone used mainly for the treatment of bacterial infections that cause exacerbation of chronic obstructive pulmonary disease, sinusitis, and community-acquired pneumonia. Unlike ciprofloxacin and levofloxacin, moxifloxacin has poor anti-pseudomonal activity.

(Choice E) Trimethoprim-sulfamethoxazole is used to treat susceptible organisms that cause urinary tract, gastrointestinal, and skin infections. It is the drug of choice for organisms such as *Pneumocystis jiroveci*, *Toxoplasma gondii*, *Nocardia*, and *Stenotrophomonas maltophilia*. It does not have activity against *P aeruginosa*.

Educational objective:

Pseudomonas aeruginosa is a major pathogen in burn patients. Only a few specific penicillins (eg, ticarcillin, piperacillin) and cephalosporins (eg, ceftazidime, cefepime) have activity against it. Certain aminoglycosides, fluoroquinolones (eg, ciprofloxacin, levofloxacin), and carbapenems (eg, imipenem, meropenem) are also effective.

References

- Update on the treatment of Pseudomonas aeruginosa pneumonia.

Settings

1
2
3
4
5
6
7
8
9
10
11
12
13
14
15
16
17
18
19
20
21
22
23
24
25
26
27
28
29
30

Item 27 of 33
Question Id: 8858

Mark | Previous | Next | Full Screen | Tutorial | Lab Values | Notes | Calculator | Reverse Color | Text Zoom | Settings

Exhibit Display

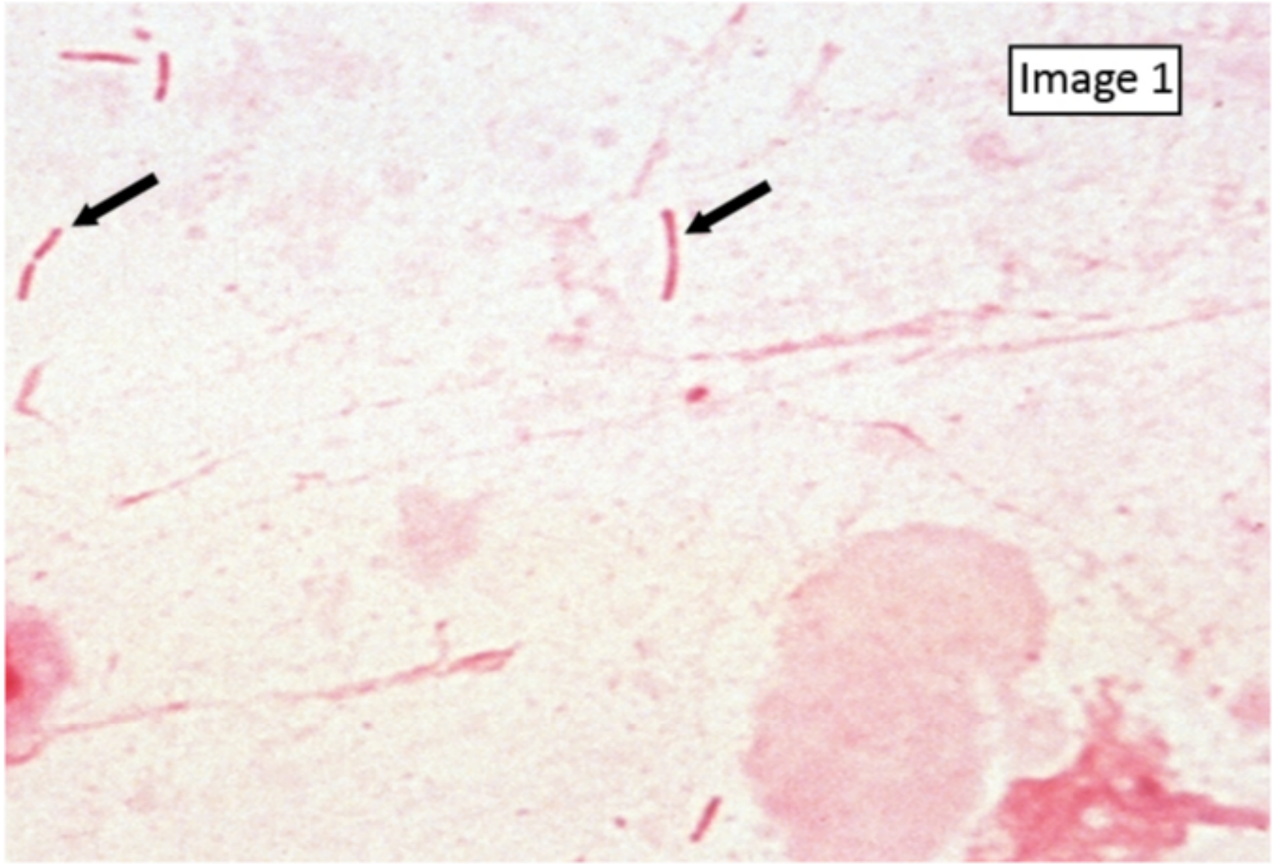

Zoom In | Zoom Out | Reset | Add To New Card | Existing Card

Block Time Remaining: 00:01:28
TUTOR

4 | Feedback | Suspend | End Block

This patient's burn is infected with Gram-negative rods that are oxidase-positive and non-lactose- fermenting, making *P aeruginosa* the most likely pathogen. Cephalosporins such as cefepime and ceftazidime have good anti-pseudomonal coverage.

(Choice B) Ceftriaxone is a third-generation cephalosporin used primarily for the treatment of community-acquired pneumonia and bacterial meningitis. It has activity against some Gram-positive (eg, *Streptococcus pneumoniae*, *S pyogenes*) and Gram-negative (eg, *Haemophilus influenzae*, *K pneumoniae*, *E coli*) pathogens. Unlike ceftazidime, it has poor activity against *P aeruginosa*.

(Choice C) Doxycycline is effective against Lyme disease and many tickborne rickettsial diseases but does not have good anti-pseudomonal coverage.

(Choice D) Moxifloxacin is a fluoroquinolone used mainly for the treatment of bacterial infections that cause exacerbation of chronic obstructive pulmonary disease, sinusitis, and community-acquired pneumonia. Unlike ciprofloxacin and levofloxacin, moxifloxacin has poor anti-pseudomonal activity.

(Choice E) Trimethoprim-sulfamethoxazole is used to treat susceptible organisms that cause urinary tract, gastrointestinal, and skin infections. It is the drug of choice for organisms such as *Pneumocystis jiroveci*, *Toxoplasma gondii*, *Nocardia*, and *Stenotrophomonas maltophilia*. It does not have activity against *P aeruginosa*.

Educational objective:

Pseudomonas aeruginosa is a major pathogen in burn patients. Only a few specific penicillins (eg, ticarcillin, piperacillin) and cephalosporins (eg, ceftazidime, cefepime) have activity against it. Certain aminoglycosides, fluoroquinolones (eg, ciprofloxacin, levofloxacin), and carbapenems (eg, imipenem, meropenem) are also effective.

References

- Update on the treatment of Pseudomonas aeruginosa pneumonia.

Microbiology	Dermatology	Skin and soft tissue infections
Subject	System	Topic

Copyright © UWorld. All rights reserved.

A 34-year-old man is admitted to the intensive care unit due to fever, chills, shortness of breath, and altered mental status. His symptoms began 3 days ago and have progressively worsened over the last 24 hours. His past medical history is significant for a motor vehicle accident 2 years ago in which he sustained blunt abdominal trauma and required emergency laparotomy due to internal bleeding. His blood pressure is 81/44 mm Hg and pulse is 122/min. He is started on broad-spectrum antibiotics, intravenous fluids, and vasopressors. His condition continues to deteriorate and he dies in the hospital several hours later despite extensive resuscitation efforts. Blood cultures obtained on admission grow *Streptococcus pneumoniae*. Impairment of which of the following mechanisms most likely contributed to the severity of this patient's infection?

A. Complement production

B. Immediate hypersensitivity

C. Intracellular killing

D. Systemic bacterial clearance

E. Type I interferon release

Submit

A 34-year-old man is admitted to the intensive care unit due to fever, chills, shortness of breath, and altered mental status. His symptoms began 3 days ago and have progressively worsened over the last 24 hours. His past medical history is significant for a motor vehicle accident 2 years ago in which he sustained blunt abdominal trauma and required emergency laparotomy due to internal bleeding. His blood pressure is 81/44 mm Hg and pulse is 122/min. He is started on broad-spectrum antibiotics, intravenous fluids, and vasopressors. His condition continues to deteriorate and he dies in the hospital several hours later despite extensive resuscitation efforts. Blood cultures obtained on admission grow *Streptococcus pneumoniae*. Impairment of which of the following mechanisms most likely contributed to the severity of this patient's infection?

- A. Complement production (25%)
- B. Immediate hypersensitivity (1%)
- C. Intracellular killing (10%)
- ✓ D. Systemic bacterial clearance (58%)
- E. Type I interferon release (3%)

Omitted
Correct answer
D

58%
Answered correctly

02 secs
Time Spent

02/10/2020
Last Updated

Explanation

Anatomy of the spleen

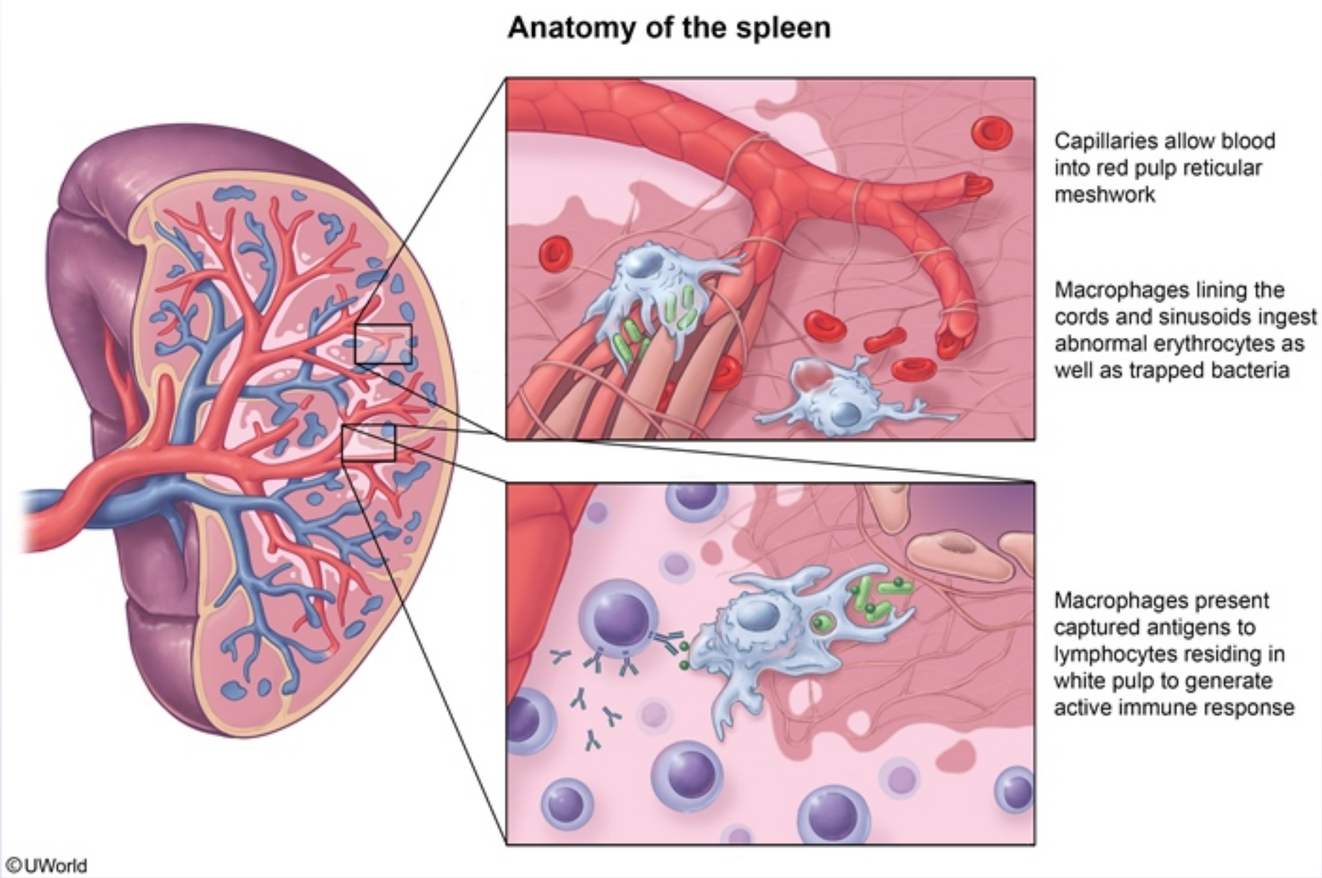

This patient likely experienced traumatic splenic rupture 2 years ago with the splenic remnants removed during laparotomy (spleen is the most commonly injured organ with blunt abdominal trauma). He subsequently experienced overwhelming **asplenic sepsis**, a condition that carries a 50% mortality risk.

The **spleen** is a part of the systemic lymphoid system and receives roughly 6% of the cardiac output. Many of the splenic capillaries are open-ended and sinusoidal, permitting whole blood to flow into the red pulp cords. These cords form a reticular meshwork that acts as a fine sieve with

©UWorld

This patient likely experienced traumatic splenic rupture 2 years ago with the splenic remnants removed during laparotomy (spleen is the most commonly injured organ with blunt abdominal trauma). He subsequently experienced overwhelming **asplenic sepsis**, a condition that carries a 50% mortality risk.

The **spleen** is a part of the systemic lymphoid system and receives roughly 6% of the cardiac output. Many of the splenic capillaries are open-ended and sinusoidal, permitting whole blood to flow into the red pulp cords. These cords form a reticular meshwork that acts as a fine sieve with spaces as small as 1 micron in diameter. Large numbers of macrophages line the red pulp cords and sinusoids and ingest any particulate matter that becomes trapped. The splenic red pulp is important for:

1. Destroying aged and **abnormal erythrocytes** (eg, spherocytes) and serving as an emergency store of blood cells and platelets that can be delivered into the circulation when needed.
2. Clearance of **circulating bacteria** that become lodged in the cords. Macrophages then present captured antigens to the B- and T-cells residing in the splenic white pulp to generate an active immune response.

Nearly half of the body's total immunoglobulins are produced by splenic B-lymphocytes. Splenic **opsonizing antibody** is of particular importance in the clearance of **encapsulated species**, as the capsule allows them to resist innate phagocytosis. Vaccination against encapsulated bacteria such as *Streptococcus pneumoniae*, *Haemophilus influenzae*, and *Neisseria meningitidis* is recommended for all asplenic patients.

(Choice A) The liver is the primary site for complement production. C3 deficiency predisposes to recurrent infections with encapsulated organisms. Deficiencies of C5-9, the components of the membrane attack complex, can lead to recurrent infections with *N meningitidis* or *N gonorrhoeae*.

(Choice B) Immediate hypersensitivity results from IgE-mediated mast cell degranulation. It is not affected by splenectomy.

(Choice C) Chronic granulomatous disease (CGD) is a condition where catalase-positive organisms such as *Staphylococcus aureus* are phagocytosed but cannot be killed effectively. Patients experience recurrent suppurative infections (eg, abscesses).

(Choice E) Interferons α and β are released from virally-infected cells and cause macrophage and cytotoxic T-lymphocyte activation, leading to destruction of infected cells. Defects in type I interferon release lead to increased susceptibility to viral infections.

Nearly half of the body's total immunoglobulins are produced by splenic B-lymphocytes. Splenic **opsonizing antibody** is of particular importance in the clearance of **encapsulated species**, as the capsule allows them to resist innate phagocytosis. Vaccination against encapsulated bacteria such as *Streptococcus pneumoniae, Haemophilus influenzae*, and *Neisseria meningitidis* is recommended for all asplenic patients.

(Choice A) The liver is the primary site for complement production. C3 deficiency predisposes to recurrent infections with encapsulated organisms. Deficiencies of C5-9, the components of the membrane attack complex, can lead to recurrent infections with *N meningitidis* or *N gonorrhoeae*.

(Choice B) Immediate hypersensitivity results from IgE-mediated mast cell degranulation. It is not affected by splenectomy.

(Choice C) Chronic granulomatous disease (CGD) is a condition where catalase-positive organisms such as *Staphylococcus aureus* are phagocytosed but cannot be killed effectively. Patients experience recurrent suppurative infections (eg, abscesses).

(Choice E) Interferons α and β are released from virally-infected cells and cause macrophage and cytotoxic T-lymphocyte activation, leading to destruction of infected cells. Defects in type I interferon release lead to increased susceptibility to viral infections.

Educational objective:
The spleen acts as both a blood filter capable of removing circulating pathogens and as a major site of opsonizing antibody synthesis. Asplenic patients are prone to infections caused by encapsulated organisms such as *Streptococcus pneumoniae, Haemophilus influenzae*, and *Neisseria meningitidis*.

References

- Pneumococcal and influenza immunization in asplenic persons: a retrospective population-based cohort study 1990-2002.
- Infections of people with complement deficiencies and patients who have undergone splenectomy.

Microbiology	Allergy & Immunology	Splenectomy
Subject	System	Topic

Copyright © UWorld. All rights reserved.

A 34-year-old woman comes to the office due to 3 days of discomfort and swelling in the right axilla. The patient has no known medical problems. She is the local community veterinarian and volunteers as a swim coach at her children's school. She owns a parrot and a hamster. Temperature is 36.9 C (98.4 F). On physical examination, there is an enlarged, tender axillary lymph node on the right, measuring about 3 cm and with slight surrounding erythema but no skin breakdown. There is no other area of lymphadenopathy present. Several scratch marks are seen on the right arm. The organism responsible for the lymphadenopathy is also associated with which of the following conditions?

- A. Bacillary angiomatosis
- B. Bladder cancer
- C. Condylomata acuminata
- D. Hemolytic uremic syndrome
- E. Malignant external otitis
- F. Toxic shock syndrome

Submit

A 34-year-old woman comes to the office due to 3 days of discomfort and swelling in the right axilla. The patient has no known medical problems. She is the local community veterinarian and volunteers as a swim coach at her children's school. She owns a parrot and a hamster. Temperature is 36.9 C (98.4 F). On physical examination, there is an enlarged, tender axillary lymph node on the right, measuring about 3 cm and with slight surrounding erythema but no skin breakdown. There is no other area of lymphadenopathy present. Several scratch marks are seen on the right arm. The organism responsible for the lymphadenopathy is also associated with which of the following conditions?

- ✓ A. Bacillary angiomatosis (83%)
- B. Bladder cancer (1%)
- C. Condylomata acuminata (3%)
- D. Hemolytic uremic syndrome (3%)
- E. Malignant external otitis (3%)
- F. Toxic shock syndrome (4%)

Omitted
Correct answer
A

83%
Answered correctly

02 secs
Time Spent

07/01/2020
Last Updated

Explanation

This patient with extensive animal exposure and scratch marks on her arm likely has **cat-scratch disease** (cat-scratch fever), a condition caused by ***Bartonella*** *henselae*. This organism resides in the oral cavity of cats and is transmitted to humans by cat scratches and bites. Typically, a primary inoculation lesion evolves from vesicular to erythematous to papular, followed by the development of **tender regional lymphadenopathy**

This patient with extensive animal exposure and scratch marks on her arm likely has **cat-scratch disease** (cat-scratch fever), a condition caused by ***Bartonella*** *henselae*. This organism resides in the oral cavity of cats and is transmitted to humans by cat scratches and bites. Typically, a primary inoculation lesion evolves from vesicular to erythematous to papular, followed by the development of **tender regional lymphadenopathy** (often involving a single lymph node) proximal to the lesion. **Axillary** lymphadenopathy is extremely common.

B henselae can also cause **bacillary angiomatosis** (BA) in immunocompromised patients. BA presents with red-purple papular skin lesions. These vascular proliferations may also be found within the viscera. BA can be fatal if left untreated.

(Choice B) *Schistosomia haematobium*, which can present acutely as swimmer's itch (organism penetration into skin) or Katayama fever (fever, urticaria, angioedema, eosinophilia), can affect the bladder (causing terminal hematuria, fibrosis); chronic infection is a risk factor for bladder cancer.

(Choice C) Condylomata acuminata (genital warts) are caused by *Human papillomavirus 6* and *11*. They present as soft, tan, cauliflowerlike masses on the penis, vulva, and perianal areas.

(Choice D) Hemolytic uremic syndrome is the triad of microangiopathic hemolytic anemia, thrombocytopenia, and renal insufficiency caused by *Escherichia coli* strain O157:H7.

(Choice E) *Pseudomonas aeruginosa* can cause malignant otitis externa in individuals using contaminated swimming pools and hot tubs. Pseudomonal hot tub folliculitis typically manifests as a rash rather than lymphadenopathy.

(Choice F) Toxic shock syndrome (TSS) is caused by *Staphylococcus aureus*. TSS presents with fever, vomiting, diarrhea, desquamation, and hypotension.

Educational objective:
Bartonella henselae causes cat-scratch disease, bacillary angiomatosis, and culture-negative endocarditis. Cat-scratch disease is characterized by low fever, lymphadenopathy, and a self-limited course.

Microbiology	Dermatology	Bartonella
Subject	System	Topic

Copyright © UWorld. All rights reserved.

Settings

1
2
3
4
5
6
7
8
9
10
11
12
13
14
15
16
17
18
19
20
21
22
23
24
25
26
27
28
29
30

Item 29 of 33
Question Id: 1898

Mark | Previous | Next | Full Screen | Tutorial | Lab Values | Notes | Calculator | Reverse Color | Text Zoom | Settings

Exhibit Display

Zoom In | Zoom Out | Reset | Add To New Card | Existing Card

(Choice E) Toxic shock syndrome (TSS) is caused by *Staphylococcus aureus*. TSS presents with fever, vomiting, diarrhea, desquamation, and

Block Time Remaining: 00:01:32
TUTOR

3 | Feedback | Suspend | End Block

During the first trimester of pregnancy, a 22-year-old immigrant from the Middle East develops a low-grade fever and maculopapular rash. Over 48 hours, the rash spreads from her face and chest to her trunk and extremities. Physical examination also detects postauricular lymphadenopathy. The mother is at risk for which of the following immediate complications (from the first column), and the fetus is at risk for which of the following congenital defects (from the second column)?

	Mother	Infant
A.	Polyarthralgia	deafness
B.	Deafness	bowlegs
C.	Polyarthralgia	macrocephaly
D.	Meningitis	malformed teeth
E.	Pneumonia	cataracts

Submit

During the first trimester of pregnancy, a 22-year-old immigrant from the Middle East develops a low-grade fever and maculopapular rash. Over 48 hours, the rash spreads from her face and chest to her trunk and extremities. Physical examination also detects postauricular lymphadenopathy. The mother is at risk for which of the following immediate complications (from the first column), and the fetus is at risk for which of the following congenital defects (from the second column)?

	Mother	Infant
✓ A. (66%)	Polyarthralgia	deafness
B. (2%)	Deafness	bowlegs
C. (8%)	Polyarthralgia	macrocephaly
D. (4%)	Meningitis	malformed teeth
E. (17%)	Pneumonia	cataracts

Omitted
Correct answer
A

66%
Answered correctly

02 secs
Time Spent

02/03/2020
Last Updated

Explanation

(17 %)

Omitted
Correct answer
A

66%
Answered correctly

02 secs
Time Spent

02/03/2020
Last Updated

Explanation

This patient's immigration history suggests that she may not have been vaccinated against measles, mumps, and rubella (MMR) at 12-15 months of age. Measles (rubeola) and German measles (rubella) are two acute viral exanthems whose maculopapular rashes begin on the head and neck and spread downward. Generalized lymphadenopathy, particularly postauricular and occipital, is typically more prominent in rubella. Most adult women with rubella develop polyarthritis and polyarthralgia as sequelae.

Fetal infection with the rubella virus during the first trimester can cause sensorineural deafness, cataracts, and cardiac malformations like a patent ductus arteriosus. Maternal deafness, meningitis, or pneumonia would be very unlikely.

(Choice D) Malformed teeth such as Hutchinson's incisors and mulberry molars are typical late manifestations of congenital syphilis.

Educational Objective:
Maternal rubella infection produces a low-grade fever, a maculopapular rash with cephalocaudal progression, and posterior auricular and suboccipital lymphadenopathy. Most adult women patients develop polyarthritis and polyarthralgia as sequelae. Congenital rubella syndrome is associated with sensorineural deafness, cataracts, and cardiac malformations (PDA).

Microbiology	Pregnancy, Childbirth & Puerperium	Rubella
Subject	System	Topic

Copyright © UWorld. All rights reserved.

A 32-year-old woman, gravida 1, para 1, comes to the office for a routine Papanicolaou test. For the past week, the patient has had a grayish-white vaginal discharge with a "fishy" odor that is not itchy or painful. She has no other concerns. Her last menstrual period was 3 weeks ago. The patient has recently become sexually active with a new partner and uses an intrauterine device for contraception. Cytology of the discharge is shown in the image below. Which of the following best describes the predominant organism of this patient's condition?

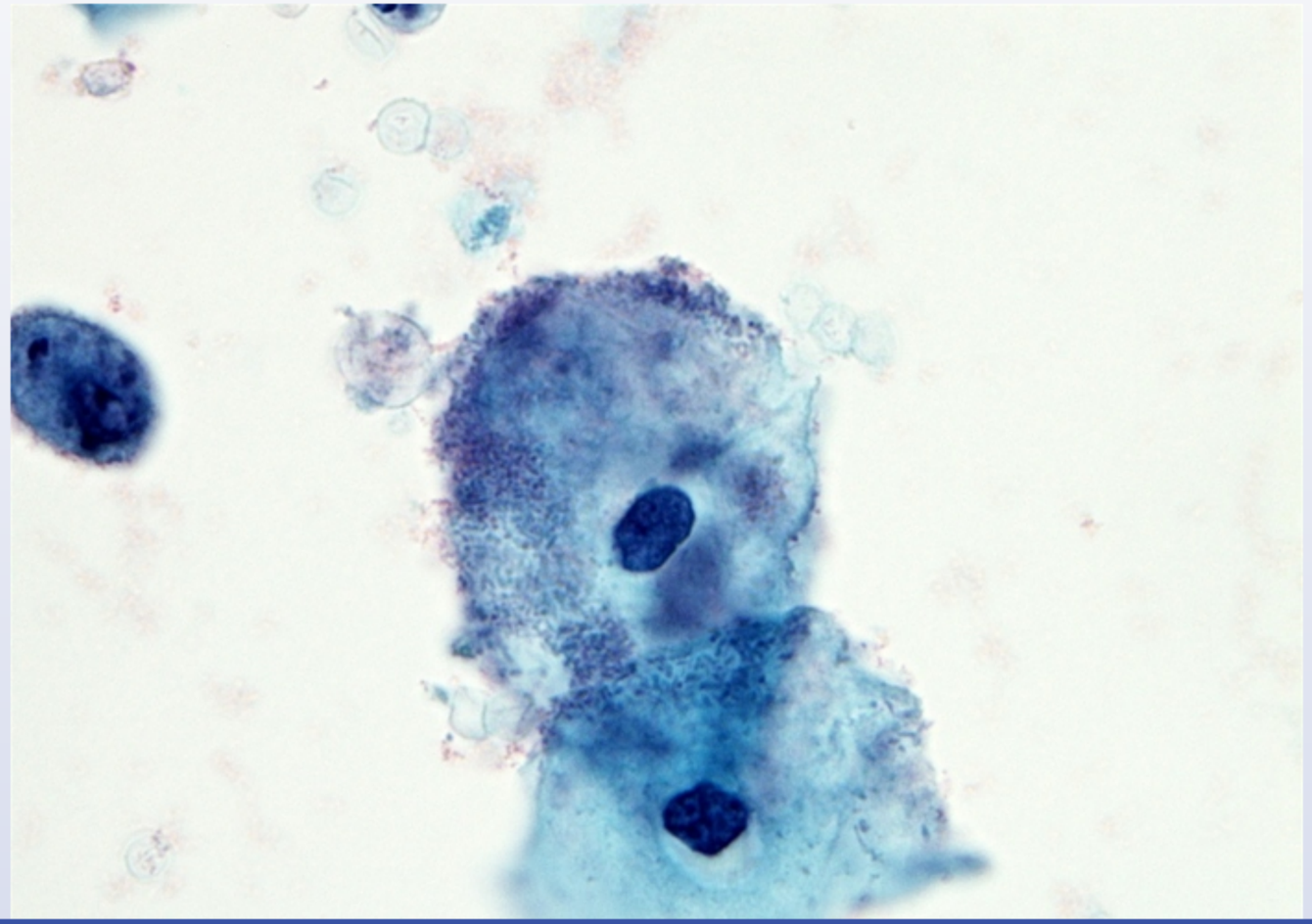

Settings

1 2 3 4 5 6 7 8 9 10 11 12 13 14 15 16 17 18 19 20 21 22 23 24 25 26 27 28 29 30

Item 31 of 33
Question Id: 1929

Mark | Previous | Next | Full Screen | Tutorial | Lab Values | Notes | Calculator | Reverse Color | Text Zoom | Settings

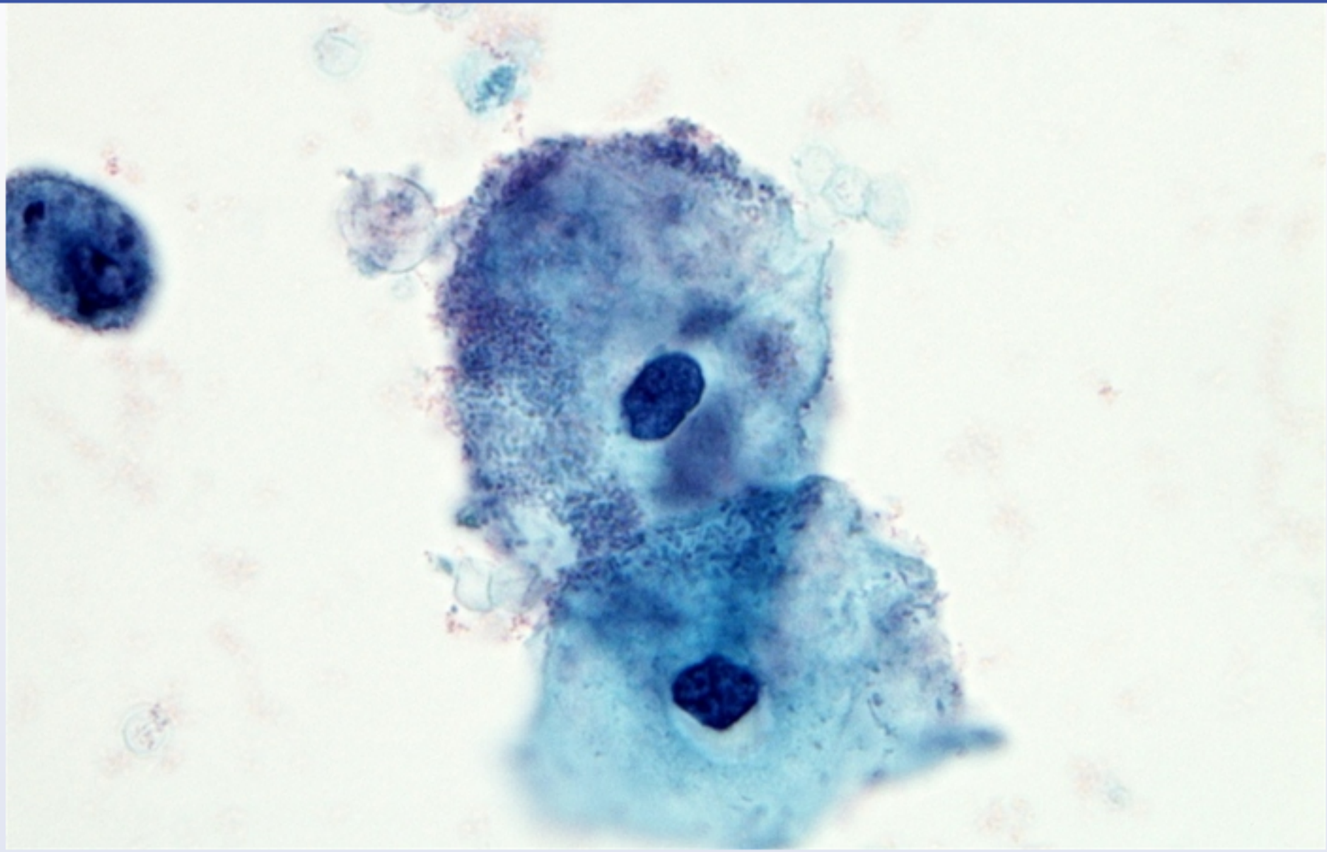

A. Anaerobic gram-variable rod

B. Diploid fungus

C. Enveloped DNA virus

D. Gram-negative diplococcus

E. Intracellular gram-negative bacterium

Block Time Remaining: 00:01:38

TUTOR

3 | Feedback | Suspend | End Block

Settings

1 2 3 4 5 6 7 8 9 10 11 12 13 14 15 16 17 18 19 20 21 22 23 24 25 26 27 28 29 30

Item 31 of 33
Question Id: 1929

Mark | Previous | Next | Full Screen | Tutorial | Lab Values | Notes | Calculator | Reverse Color | Text Zoom | Settings

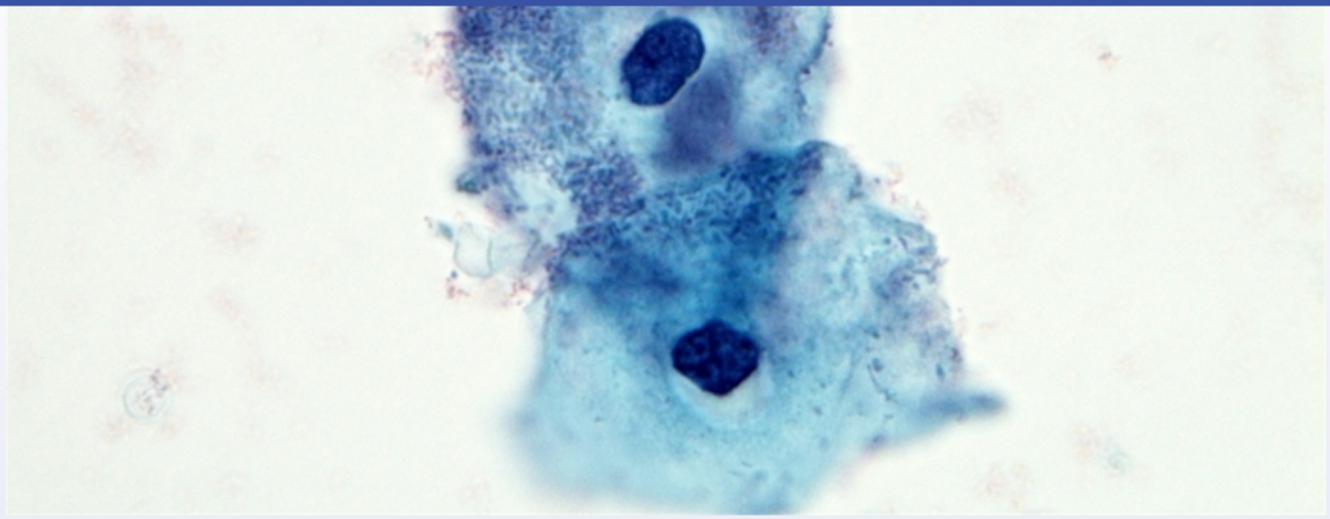

A. Anaerobic gram-variable rod

B. Diploid fungus

C. Enveloped DNA virus

D. Gram-negative diplococcus

E. Intracellular gram-negative bacterium

F. Motile protozoan

G. Naked DNA virus

Submit

Block Time Remaining: 00:01:39
TUTOR

3 | Feedback | Suspend | End Block

Settings

1 2 3 4 5 6 7 8 9 10 11 12 13 14 15 16 17 18 19 20 21 22 23 24 25 26 27 28 29 30

Item 31 of 33
Question Id: 1929

Mark | Previous | Next | Full Screen | Tutorial | Lab Values | Notes | Calculator | Reverse Color | Text Zoom | Settings

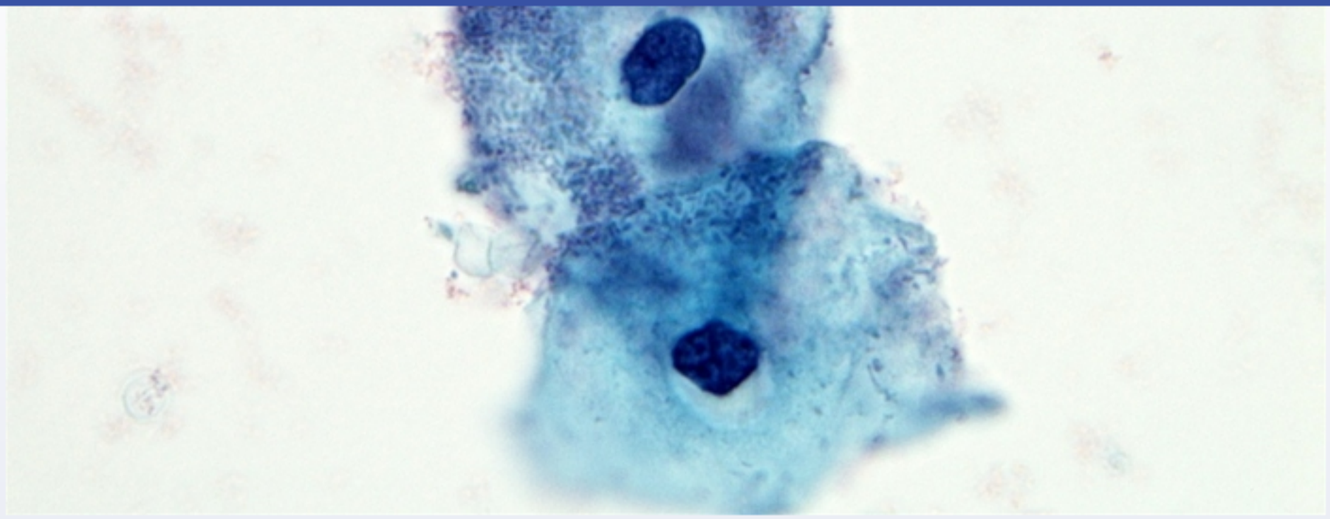

- ✓ A. Anaerobic gram-variable rod (65%)
- B. Diploid fungus (2%)
- C. Enveloped DNA virus (2%)
- D. Gram-negative diplococcus (4%)
- E. Intracellular gram-negative bacterium (14%)
- F. Motile protozoan (10%)
- G. Naked DNA virus (2%)

Omitted
Correct answer

65%
Answered correctly

07 secs
Time Spent

06/27/2020
Last Updated

Block Time Remaining: 00:01:41
TUTOR

3 | Feedback | Suspend | End Block

Differential diagnosis of vaginitis

Diagnosis	Bacterial vaginosis (*Gardnerella vaginalis*)	Trichomoniasis (*Trichomonas vaginalis*)	Candida vaginitis (*Candida albicans*)
Examination	 • Thin, off-white discharge with fishy odor • No inflammation	 • Thin, yellow-green, malodorous, frothy discharge • Vaginal inflammation	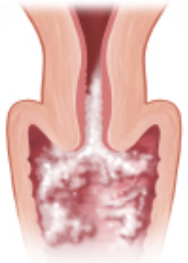 • Thick, "cottage cheese" discharge • Vaginal inflammation
Laboratory findings	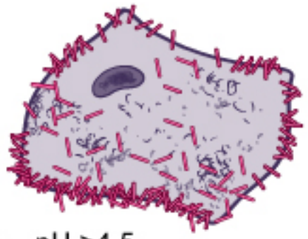 • pH >4.5 • Clue cells • Positive whiff test (amine odor with KOH)	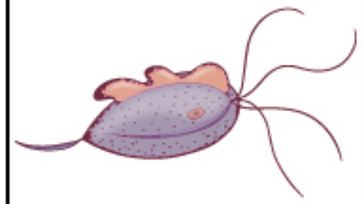 • pH >4.5 • Motile trichomonads	 • Normal pH (3.8-4.5) • Pseudohyphae
Treatment	Metronidazole or clindamycin	Metronidazole; treat sexual partner	Fluconazole

KOH = potassium hydroxide

©UWorld

Bacterial vaginosis is most commonly caused by an overgrowth of the **anaerobic gram-variable rod** *Gardnerella vaginalis* and loss of normal lactobacilli flora. Classic symptoms include a **grayish-white discharge** with a **"fishy" odor** that becomes more prominent with addition of **potassium hydroxide** (the **Whiff test**). Wet mount microscopy of the discharge and cytologic smears characteristically show clue cells. Clue cells are vaginal, squamous epithelial cells covered with multiple, small, adherent *G vaginalis* organisms. Unlike trichomoniasis or *Candida* vulvovaginitis, there is no vaginal inflammation. Bacterial vaginosis can be treated with **metronidazole** or **clindamycin**.

(Choice B) *Candida albicans* vaginitis is associated with intense vaginal pruritus, white curd-like discharge, and labial erythema. Clue cells are not present. Pseudohyphae of this diploid fungus are seen on potassium hydroxide preparations of the vaginal discharge.

(Choice C) Herpes simplex virus (HSV) infection, particularly type 2, causes painful vesicles, erosions, and ulcerations of the cervix that may result in vaginal discharge. HSV is an enveloped DNA virus, and cervical cytology would show multinucleated giant cells with intranuclear inclusions.

(Choices D and E) *Neisseria gonorrhoeae* (a gram-negative diplococcus) and *Chlamydia trachomatis* (an intracellular gram-negative bacterium) are commonly transmitted together sexually. These organisms can cause cervicitis, which can then progress to pelvic inflammatory disease. Affected patients are diagnosed via nucleic acid amplification tests or culture.

(Choice F) *Trichomonas vaginalis* is a flagellated protozoan that causes trichomoniasis, which is associated with a yellow-green, foamy, and foul-smelling discharge. Motile, flagellated trophozoites are seen on wet mount microscopy.

(Choice G) Human papillomavirus is a naked DNA virus that can cause condyloma acuminata and cervical cancer. Condylomas are typically caused by strains 6 and 11. Oncogenic strains include 16 and 18.

Educational objective:
Bacterial vaginosis is associated with a grayish-white vaginal discharge with a "fishy" odor. The etiology involves an overgrowth of *Gardnerella vaginalis*, an anaerobic gram-variable rod. Clue cells (squamous epithelial cells covered with bacterial organisms) are seen on wet mount microscopy or cytology.

References

- ACOG Practice Bulletin. Clinical management guidelines for obstetrician-gynecologists. Number 72. May 2006: Vaginitis.

(Choice B) *Candida albicans* vaginitis is associated with intense vaginal pruritus, white curd-like discharge, and labial erythema. Clue cells are not present. Pseudohyphae of this diploid fungus are seen on potassium hydroxide preparations of the vaginal discharge.

(Choice C) Herpes simplex virus (HSV) infection, particularly type 2, causes painful vesicles, erosions, and ulcerations of the cervix that may result in vaginal discharge. HSV is an enveloped DNA virus, and cervical cytology would show multinucleated giant cells with intranuclear inclusions.

(Choices D and E) *Neisseria gonorrhoeae* (a gram-negative diplococcus) and *Chlamydia trachomatis* (an intracellular gram-negative bacterium) are commonly transmitted together sexually. These organisms can cause cervicitis, which can then progress to pelvic inflammatory disease. Affected patients are diagnosed via nucleic acid amplification tests or culture.

(Choice F) *Trichomonas vaginalis* is a flagellated protozoan that causes trichomoniasis, which is associated with a yellow-green, foamy, and foul-smelling discharge. Motile, flagellated trophozoites are seen on wet mount microscopy.

(Choice G) Human papillomavirus is a naked DNA virus that can cause condyloma acuminata and cervical cancer. Condylomas are typically caused by strains 6 and 11. Oncogenic strains include 16 and 18.

Educational objective:
Bacterial vaginosis is associated with a grayish-white vaginal discharge with a "fishy" odor. The etiology involves an overgrowth of *Gardnerella vaginalis*, an anaerobic gram-variable rod. Clue cells (squamous epithelial cells covered with bacterial organisms) are seen on wet mount microscopy or cytology.

References

- ACOG Practice Bulletin. Clinical management guidelines for obstetrician-gynecologists, Number 72, May 2006: Vaginitis.

Microbiology	Female Reproductive System & Breast	Bacterial vaginosis
Subject	System	Topic

Copyright © UWorld. All rights reserved.

Treatment	or clindamycin	sexual partner	Fluconazole

Exhibit Display

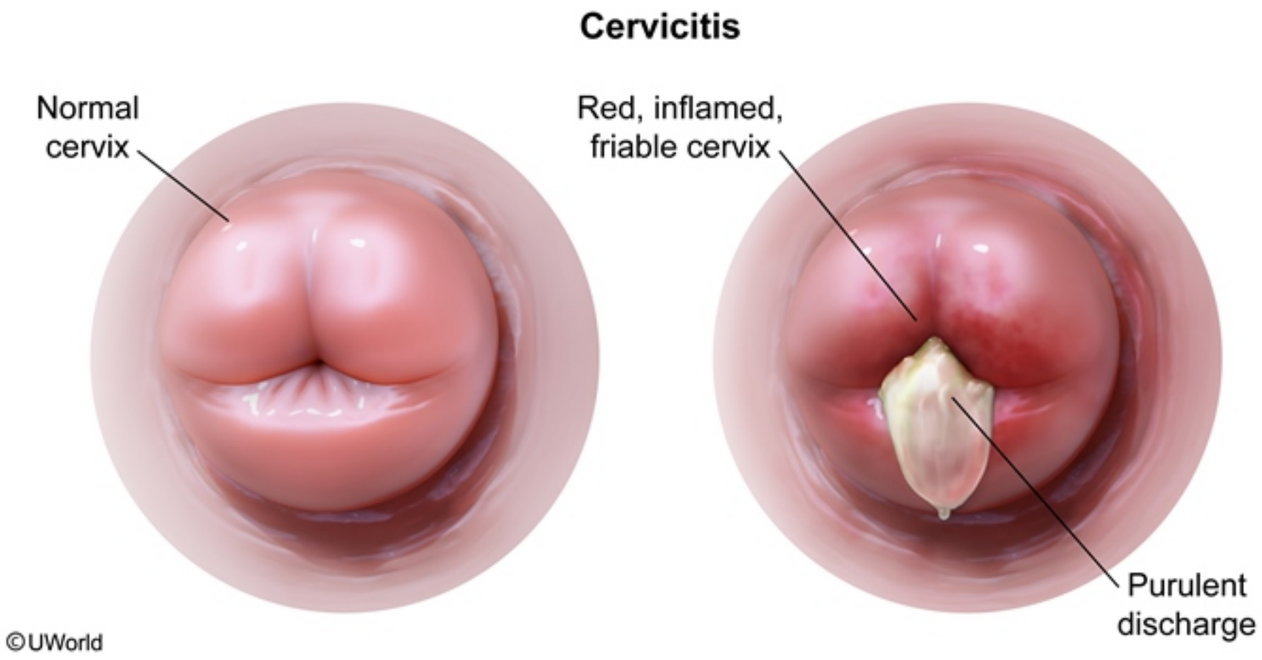

Zoom In | Zoom Out | Reset | Add To New Card | Existing Card

Settings

1 2 3 4 5 6 7 8 9 10 11 12 13 14 15 16 17 18 19 20 21 22 23 24 25 26 27 28 29 30

Item 31 of 33
Question Id: 1929

Mark | Previous | Next | Full Screen | Tutorial | Lab Values | Notes | Calculator | Reverse Color | Text Zoom | Settings

Exhibit Display

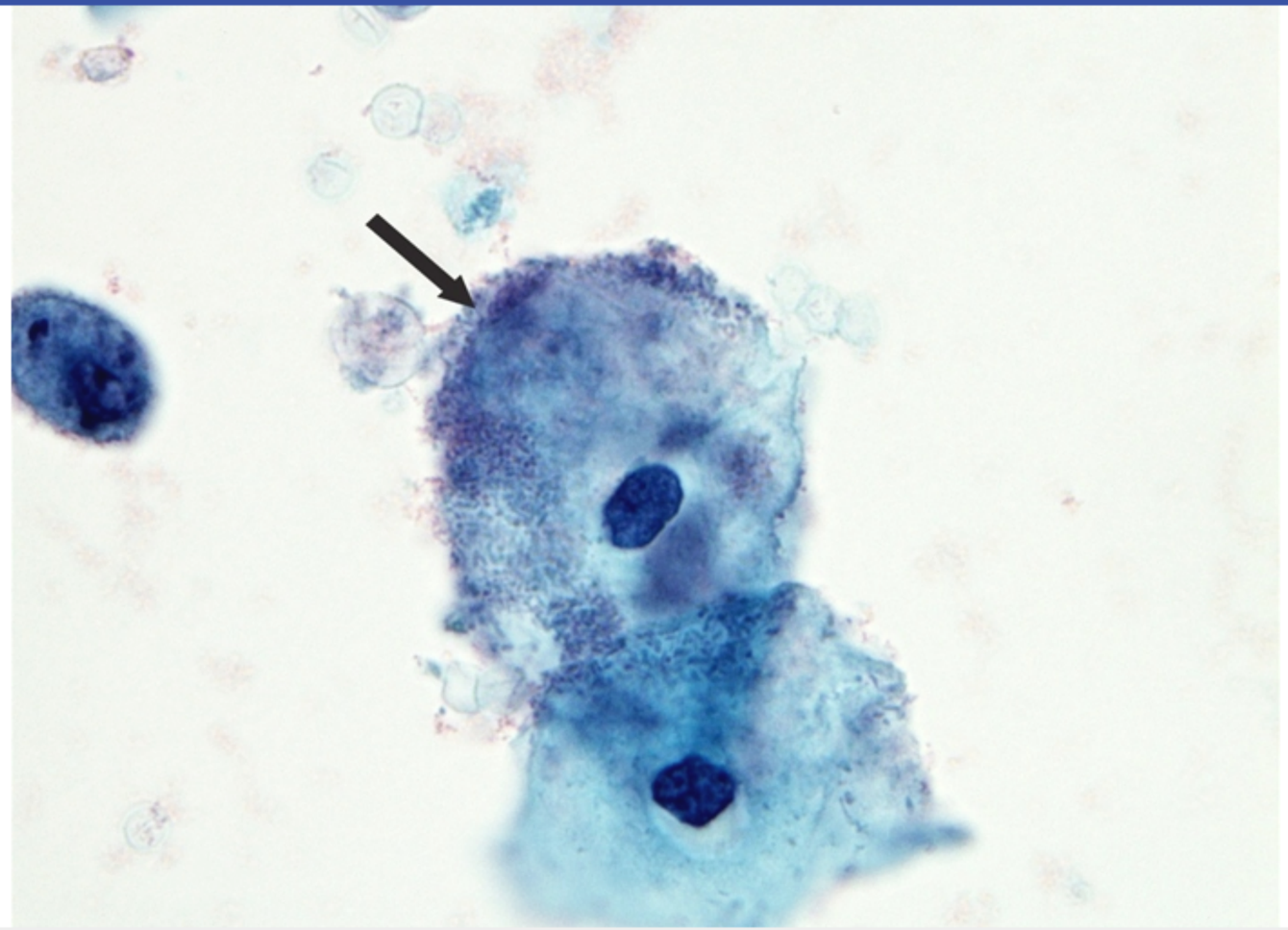

Zoom In | Zoom Out | Reset | Add To New Card | Existing Card

Block Time Remaining: 00:01:41
TUTOR

3 | Feedback | Suspend | End Block

(Choice B) *Candida albicans* vaginitis is associated with intense vaginal pruritus, white curd-like discharge, and labial erythema. Clue cells are not present. Pseudohyphae of this diploid fungus are seen on potassium hydroxide preparations of the vaginal discharge.

(Choice C) Herpes simplex virus (HSV) infection, particularly type 2, causes painful vesicles, erosions, and ulcerations of the cervix that may result in vaginal discharge. HSV is an enveloped DNA virus, and cervical cytology would show multinucleated giant cells with intranuclear inclusions.

(Choices D and E) *Neisseria gonorrhoeae* (a gram-negative diplococcus) and *Chlamydia trachomatis* (an intracellular gram-negative bacterium) are commonly transmitted together sexually. These organisms can cause cervicitis, which can then progress to pelvic inflammatory disease. Affected patients are diagnosed via nucleic acid amplification tests or culture.

(Choice F) *Trichomonas vaginalis* is a flagellated protozoan that causes trichomoniasis, which is associated with a yellow-green, foamy, and foul-smelling discharge. Motile, flagellated trophozoites are seen on wet mount microscopy.

(Choice G) Human papillomavirus is a naked DNA virus that can cause condyloma acuminata and cervical cancer. Condylomas are typically caused by strains 6 and 11. Oncogenic strains include 16 and 18.

Educational objective:
Bacterial vaginosis is associated with a grayish-white vaginal discharge with a "fishy" odor. The etiology involves an overgrowth of *Gardnerella vaginalis*, an anaerobic gram-variable rod. Clue cells (squamous epithelial cells covered with bacterial organisms) are seen on wet mount microscopy or cytology.

References

- ACOG Practice Bulletin. Clinical management guidelines for obstetrician-gynecologists, Number 72, May 2006: Vaginitis.

Microbiology	Female Reproductive System & Breast	Bacterial vaginosis
Subject	System	Topic

Copyright © UWorld. All rights reserved.

A 38-year-old woman comes to the office for evaluation of a skin lesion. It began as a pink papule on her right arm and has progressively enlarged over several weeks. The lesion is not pruritic or painful and has not been associated with fever or other systemic symptoms. The patient returned from a trip to Costa Rica 5 weeks ago. During her travel, she stayed at a beachside resort and hiked in the rainforest. Skin examination findings are shown below. Biopsy of the lesion reveals intracellular, round-oval protozoa with rod-shaped kinetoplasts. Which of the following most likely led to this patient's current condition?

A. Bite from infected sand fly

B. Contact with infected person

C. Exposure to decaying vegetation

D. Handling of infected animal

E. Swimming in contaminated water

Submit

A 38-year-old woman comes to the office for evaluation of a skin lesion. It began as a pink papule on her right arm and has progressively enlarged over several weeks. The lesion is not pruritic or painful and has not been associated with fever or other systemic symptoms. The patient returned from a trip to Costa Rica 5 weeks ago. During her travel, she stayed at a beachside resort and hiked in the rainforest. Skin examination findings are shown below. Biopsy of the lesion reveals intracellular, round-oval protozoa with rod-shaped kinetoplasts. Which of the following most likely led to this patient's current condition?

Settings

1 2 3 4 5 6 7 8 9 10 11 12 13 14 15 16 17 18 19 20 21 22 23 24 25 26 27 28 29 30

Item 32 of 33
Question Id: 15448

Mark | Previous | Next | Full Screen | Tutorial | Lab Values | Notes | Calculator | Reverse Color | Text Zoom | Settings

A. Bite from infected sand fly

B. Contact with infected person

C. Exposure to decaying vegetation

D. Handling of infected animal

E. Swimming in contaminated water

Submit

Block Time Remaining: 00:01:47
TUTOR

4 | Feedback | Suspend | End Block

Settings

1 2 3 4 5 6 7 8 9 10 11 12 13 14 15 16 17 18 19 20 21 22 23 24 25 26 27 28 29 30

Item 32 of 33
Question Id: 15448

Mark | Previous | Next | Full Screen | Tutorial | Lab Values | Notes | Calculator | Reverse Color | Text Zoom | Settings

- A. Bite from infected sand fly (52%)
- B. Contact with infected person (4%)
- C. Exposure to decaying vegetation (7%)
- D. Handling of infected animal (7%)
- E. Swimming in contaminated water (29%)

Omitted | 52% | 08 secs | 02/17/2020

Block Time Remaining: 00:01:49
TUTOR

4 | Feedback | Suspend | End Block

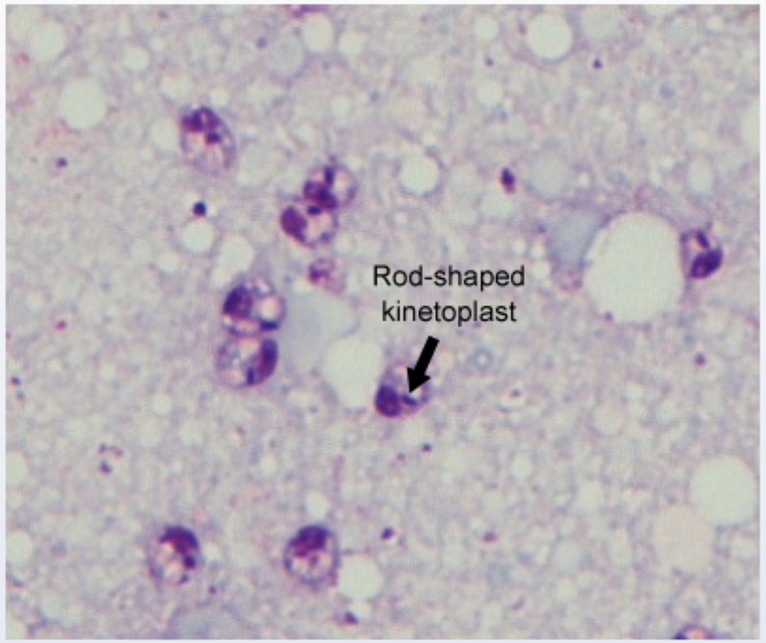

Microscopy of this patient's skin lesion revealed intracellular protozoa with rod-shaped kinetoplasts, raising strong suspicion for **cutaneous leishmaniasis**, a parasitic disease endemic to the Middle East and Central and South America. *Leishmania* species are harbored by small mammals and transmitted to humans via bites from **infected sand flies**. The parasite subsequently matures within mammalian macrophages and can be visualized on biopsy as **intracellular**, **round-oval** amastigotes with **rod-shaped kinetoplasts** (see arrow).

Cutaneous leishmaniasis is characterized by a chronic, **enlarging, pinkish papule** at the site of the bite that eventually develops into a nodule or **plaque** and ulcerates. Most cases occur on exposed areas of skin because sand fly bites cannot penetrate clothing. More serious mucosal or lymphatic *Leishmania* infections can also occur.

(Choice B) Yaws, a spirochetal infection caused by *Treponema pallidium* subspecies, is transmitted by skin-to-skin (nonsexual) contact and is seen in Central America. Patients typically develop a painless papule that eventually ulcerates (similar to syphilitic chancre). However, this organism is a bacterium, not a protozoan.

Microscopy of this patient's skin lesion revealed intracellular protozoa with rod-shaped kinetoplasts, raising strong suspicion for **cutaneous leishmaniasis**, a parasitic disease endemic to the Middle East and Central and South America. *Leishmania* species are harbored by small mammals and transmitted to humans via bites from **infected sand flies**. The parasite subsequently matures within mammalian macrophages and can be visualized on biopsy as **intracellular**, **round-oval** amastigotes with **rod-shaped kinetoplasts** (see arrow).

Cutaneous leishmaniasis is characterized by a chronic, **enlarging, pinkish papule** at the site of the bite that eventually develops into a nodule or **plaque** and ulcerates. Most cases occur on exposed areas of skin because sand fly bites cannot penetrate clothing. More serious mucosal or lymphatic *Leishmania* infections can also occur.

(Choice B) Yaws, a spirochetal infection caused by *Treponema pallidium* subspecies, is transmitted by skin-to-skin (nonsexual) contact and is seen in Central America. Patients typically develop a painless papule that eventually ulcerates (similar to syphilitic chancre). However, this organism is a bacterium, not a protozoan.

(Choice C) *Sporothrix schenckii*, a dimorphic fungus, grows in decaying plant matter and is transmitted to humans via subcutaneous inoculation. Manifestations include a papule at the site of inoculation and subsequent papules along proximal lymphatic drainage pathways. Histopathology demonstrates granulomas and cigar-shaped, budding fungus.

(Choice D) *Bacillus anthracis*, a gram-positive bacterial infection, is often transmitted to humans due to cutaneous contact with infected animals or animal hides. Manifestations include a painless cutaneous papule that evolves over days into an ulcer with a black eschar. Histopathology would show extracellular, gram-positive rods.

(Choice E) *Mycobacterium marinum*, an acid-fast bacterium, causes cutaneous infection after exposure to contaminated water (eg, fish tank). Patients typically develop a papule that ulcerates and scars. However, histopathology would not show intracellular protozoa.

Educational objective:
Leishmania species are obligate intracellular protozoa that mature in macrophages and can be identified on biopsy by the presence of rod-shaped kinetoplasts. They are transmitted to humans by infected sand flies and cause the clinical syndrome of cutaneous leishmaniasis, characterized by a chronic, pinkish papule that evolves into a nodule or plaque.

Microbiology Dermatology Leishmaniasis

can be visualized on biopsy as **intracellular**, **round-oval** amastigotes with **rod-shaped kinetoplasts** (see arrow).

Cutaneous leishmaniasis is characterized by a chronic, **enlarging, pinkish papule** at the site of the bite that eventually develops into a nodule or **plaque** and ulcerates. Most cases occur on exposed areas of skin because sand fly bites cannot penetrate clothing. More serious mucosal or lymphatic *Leishmania* infections can also occur.

(Choice B) Yaws, a spirochetal infection caused by *Treponema pallidium* subspecies, is transmitted by skin-to-skin (nonsexual) contact and is seen in Central America. Patients typically develop a painless papule that eventually ulcerates (similar to syphilitic chancre). However, this organism is a bacterium, not a protozoan.

(Choice C) *Sporothrix schenckii*, a dimorphic fungus, grows in decaying plant matter and is transmitted to humans via subcutaneous inoculation. Manifestations include a papule at the site of inoculation and subsequent papules along proximal lymphatic drainage pathways. Histopathology demonstrates granulomas and cigar-shaped, budding fungus.

(Choice D) *Bacillus anthracis*, a gram-positive bacterial infection, is often transmitted to humans due to cutaneous contact with infected animals or animal hides. Manifestations include a painless cutaneous papule that evolves over days into an ulcer with a black eschar. Histopathology would show extracellular, gram-positive rods.

(Choice E) *Mycobacterium marinum*, an acid-fast bacterium, causes cutaneous infection after exposure to contaminated water (eg, fish tank). Patients typically develop a papule that ulcerates and scars. However, histopathology would not show intracellular protozoa.

Educational objective:
Leishmania species are obligate intracellular protozoa that mature in macrophages and can be identified on biopsy by the presence of rod-shaped kinetoplasts. They are transmitted to humans by infected sand flies and cause the clinical syndrome of cutaneous leishmaniasis, characterized by a chronic, pinkish papule that evolves into a nodule or plaque.

Microbiology	Dermatology	Leishmaniasis
Subject	System	Topic

Copyright © UWorld. All rights reserved.

A 68-year-old woman comes to the office for evaluation of a skin rash. The patient says that red, painful papules erupted on her right chest 5 days ago and quickly turned into vesicles containing clear fluid. The lesions are now beginning to crust and are less painful. She has never had similar lesions and does not recall coming into contact with a person having a similar illness. Medical history is significant only for well-controlled hypertension. Physical examination shows a grouped vesicular rash involving the right T4 dermatome that is beginning to heal with crusting. The rash does not cross the midline. Lightly touching the skin elicits sharp pain. The remainder of the examination shows no abnormalities. This patient is at greatest risk of developing which of the following complications as a result of her current condition?

- A. Dissemination of rash to other body areas
- B. Painful swelling of the large joints
- C. Persistent pain in the affected region
- D. Recurrent episodes of gross hematuria
- E. Sensory loss in "glove and stocking" pattern

Submit

A 68-year-old woman comes to the office for evaluation of a skin rash. The patient says that red, painful papules erupted on her right chest 5 days ago and quickly turned into vesicles containing clear fluid. The lesions are now beginning to crust and are less painful. She has never had similar lesions and does not recall coming into contact with a person having a similar illness. Medical history is significant only for well-controlled hypertension. Physical examination shows a grouped vesicular rash involving the right T4 dermatome that is beginning to heal with crusting. The rash does not cross the midline. Lightly touching the skin elicits sharp pain. The remainder of the examination shows no abnormalities. This patient is at greatest risk of developing which of the following complications as a result of her current condition?

A. Dissemination of rash to other body areas (3%)

B. Painful swelling of the large joints (3%)

✓ C. Persistent pain in the affected region (85%)

D. Recurrent episodes of gross hematuria (1%)

E. Sensory loss in "glove and stocking" pattern (6%)

Omitted
Correct answer
C

85%
Answered correctly

02 secs
Time Spent

03/23/2020
Last Updated

Explanation

This patient has a vesicular rash consistent with **herpes zoster** (shingles), which is caused by reactivation of latent varicella-zoster virus (VZV) infection. Following the primary infection (**chickenpox**), VZV remains dormant in the **dorsal root ganglia** until emerging decades later. Decreased cell-mediated immunity (eg, older age, immunosuppressive medications, HIV infection) increases the risk of reactivation.

This patient has a vesicular rash consistent with **herpes zoster** (shingles), which is caused by reactivation of latent varicella-zoster virus (VZV) infection. Following the primary infection (**chickenpox**), VZV remains dormant in the **dorsal root ganglia** until emerging decades later. Decreased cell-mediated immunity (eg, older age, immunosuppressive medications, HIV infection) increases the risk of reactivation.

Reactivation of VZV causes hemorrhagic inflammation of the dorsal root ganglion and peripheral nerve. The resulting hypersensitive nerve function presents with **neuropathic pain** in the affected region (herpetic neuralgia), typically described as stabbing, tingling, or burning. Herpetic neuralgia can begin even before the appearance of skin lesions and may persist for up to several months. A minority of patients experience **long-term residual pain**, termed **postherpetic neuralgia**; the risk is greater in older patients (age >70) and those with more severe shingles.

(Choice A) Primary VZV infection is characterized by a diffuse vesicular rash (chickenpox), but reactivation is dermatomal. Generalized reactivation or spread to other body areas can occur in immune-compromised patients but is extremely rare in healthy individuals.

(Choice B) Reactive arthritis presents with an asymmetric peripheral oligoarthritis, often with extraarticular symptoms (eg, uveitis, conjunctivitis, urethritis). It typically follows bacterial gastrointestinal (eg, *Salmonella*, *Shigella*, *Campylobacter*) or genitourinary (eg, *Chlamydia*) infection.

(Choice D) IgA nephropathy produces recurrent glomerulonephritis and typically presents with episodic hematuria. Common triggers include upper respiratory illness, but shingles does not typically exacerbate the condition.

(Choice E) Toxic or metabolic nerve injury (eg, diabetic peripheral neuropathy) is typically proportionate to the length of the sensory nerve fibers. Symptoms appear first in the longest nerves, such as those to the feet and hands, causing a "glove and stocking" distribution. However, because reactivation of VZV occurs only in specific sensory ganglia, symptoms have a dermatomal distribution.

Educational objective:
A unilateral vesicular rash localized on a single dermatome in an older patient is most likely herpes zoster. Postherpetic neuralgia is the most common neurologic complication of varicella zoster virus infection.

Microbiology	Dermatology	Herpes zoster
Subject	System	Topic

Copyright © UWorld. All rights reserved.

This patient has a vesicular rash consistent with **herpes zoster** (shingles), which is caused by reactivation of latent varicella-zoster virus (VZV) infection. Following the primary infection (**chickenpox**), VZV remains dormant in the **dorsal root ganglia** until emerging decades later. Decreased cell-mediated immunity (eg, older age, immunosuppressive medications, HIV infection) increases the risk of reactivation.

Reactivation of VZV causes hemorrhagic inflammation of the dorsal root ganglion and peripheral nerve. The resulting hypersensitive nerve function presents with **neuropathic pain** in the affected region (herpetic neuralgia), typically described as stabbing, tingling, or burning. Herpetic neuralgia can begin even before the appearance of skin lesions and may persist for up to several months. A minority of patients experience **long-term residual pain**, termed **postherpetic neuralgia**; the risk is greater in older patients (age >70) and those with more severe shingles.

(Choice A) Primary VZV infection is characterized by a diffuse vesicular rash (chickenpox), but reactivation is dermatomal. Generalized reactivation or spread to other body areas can occur in immune-compromised patients but is extremely rare in healthy individuals.

(Choice B) Reactive arthritis presents with an asymmetric peripheral oligoarthritis, often with extraarticular symptoms (eg, uveitis, conjunctivitis, urethritis). It typically follows bacterial gastrointestinal (eg, *Salmonella*, *Shigella*, *Campylobacter*) or genitourinary (eg, *Chlamydia*) infection.

(Choice D) IgA nephropathy produces recurrent glomerulonephritis and typically presents with episodic hematuria. Common triggers include upper respiratory illness, but shingles does not typically exacerbate the condition.

(Choice E) Toxic or metabolic nerve injury (eg, diabetic peripheral neuropathy) is typically proportionate to the length of the sensory nerve fibers. Symptoms appear first in the longest nerves, such as those to the feet and hands, causing a "glove and stocking" distribution. However, because reactivation of VZV occurs only in specific sensory ganglia, symptoms have a dermatomal distribution.

Educational objective:
A unilateral vesicular rash localized on a single dermatome in an older patient is most likely herpes zoster. Postherpetic neuralgia is the most common neurologic complication of varicella zoster virus infection.

Microbiology	Dermatology	Herpes zoster
Subject	System	Topic

Copyright © UWorld. All rights reserved.